

Overlooked Posterior Shoulder Dislocation: Preoperative and Postoperative CT Studies. A Case Report.

Cemil Kayali^{1(A,B,C,D,E,F)}, **Haluk Agus**^{1(A,B,C,D,E,F)}, **Onder Kalenderer**^{1(A,B,C,D,E,F)},
Ali Turgut^{1(A,B,C,D,E,F)}, **Tuna Imamoglu**^{2(A,B,C,D,E,F)}

¹ Tepecik Education and Research Hospital, II. Orthopaedics and Traumatology Clinics

² Tepecik Education and Research Hospital, Radiodiagnostic Clinics

SUMMARY

Posterior shoulder dislocation is an extremely rare injury. A radiograph of the dislocated shoulder is generally accepted as normal owing to several traps. Therefore if the clinician is not suspicious, this injury can easily be overlooked. Most of the cases described in the literature were overlooked dislocations reported as case reports or series. We aimed to present a case of sustained posterior shoulder dislocation. The injury was initially overlooked, the patient was admitted 1 month later and treated by modified McLaughlin procedure.

Key words: shoulder dislocation, posterior, open reduction, subscapularis tendon

BACKGROUND

Posterior shoulder dislocation accounts for 2% of all shoulder dislocations, thus representing a rarely seen orthopaedic injury [1, 2]. Therefore there is limited knowledge about classification or prognosis and no definitive algorithm available for treatment. Closed reduction, anatomical or non-anatomical soft tissue and bone procedures following open reduction, and shoulder arthroplasty have been proposed as treatments [3,4,5,6,7].

Another property of that injury is that, although clinical findings include some clues, shoulder joint radiographs have some traps [8]. If the physician has not enough experience, it can easily be overlooked in a patient with restriction of shoulder movements and pain, but with near to normal X-ray findings [9].

In this case report we present a case of a sustained (initially overlooked) posterior shoulder dislocation of one month's duration.

CASE REPORT

A 51-year-old man was admitted to a private medical centre on account of pain after hitting a wall at a speed with both arms in an ante-flexed position. He was diagnosed with soft tissue injury after clinical and radiological evaluations (Figure 1). One month later his pain and shoulder disability had not resolved. Therefore he was admitted to our outpatient clinic.

Pain was detected by palpation of the joint. The range of motion (ROM) was severely restricted at 30° abduction and 20° flexion with no rotation. An axillary view X-ray could not be obtained because of intense pain. Computed tomography (CT) and mag-

netic resonance imaging (MRI) exams were carried out due to a suspected posterior shoulder dislocation (Figure 2, 3)

Posterior shoulder dislocation was clearly identified on CT images. In addition an impression fracture of the antero-medial side of the humeral head (reverse Hill-Sachs lesion) was observed. The humeral head was locked from the Hill-Sachs lesion to the posterior rim of the glenoid. The impression fracture occupied nearly 25% of the articular surface of the humeral head. Bone marrow edema of the humeral head, increased fluid in the joint space, bone fragments, anterior capsule separation from the glenoid anterior rim, and medial transposition of the biceps tendon were determined on MRI images.

The patient underwent elective surgery. A closed reduction was first attempted with one Steinman wire in the humeral head as a joystick technique. The decision to perform an open reduction was taken after failure of the closed reduction. A Delto-pectoral incision was used to reach the shoulder joint. The anterior part of the capsule was found to be detached from the glenoid rim. Open reduction was achieved after unlocking of the humeral head from the glenoid after evacuation of intra-articular debris. The articular surface of the humeral head on the impression side had been crushed. The shoulder joint was not stable in adduction and internal rotation. Then a bone block was released from the insertion side of the subscapularis at the tuberculum minus by using an osteotome. It was transferred to the impression side of the humeral head with one malleolar screw (Figure 4) and the joint was stable intraoperatively. The anterior portion of the joint capsule was repaired.

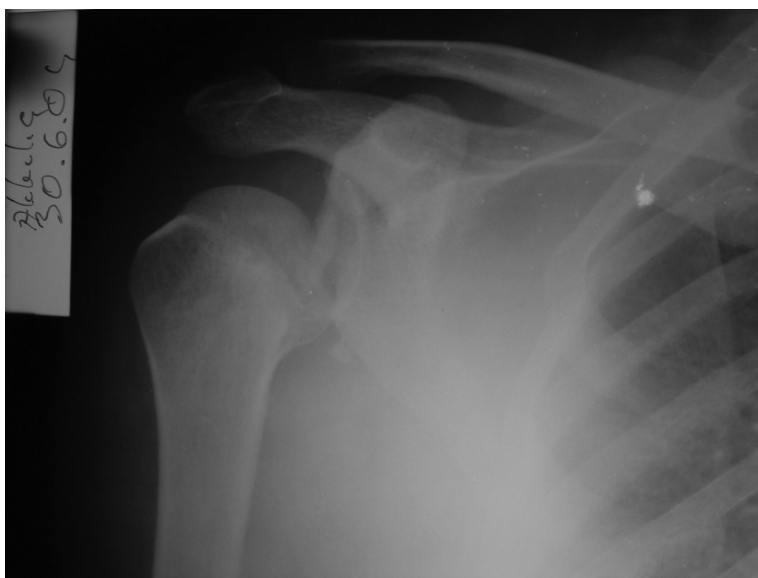

Fig. 1. Preoperative antero-posterior shoulder X-ray

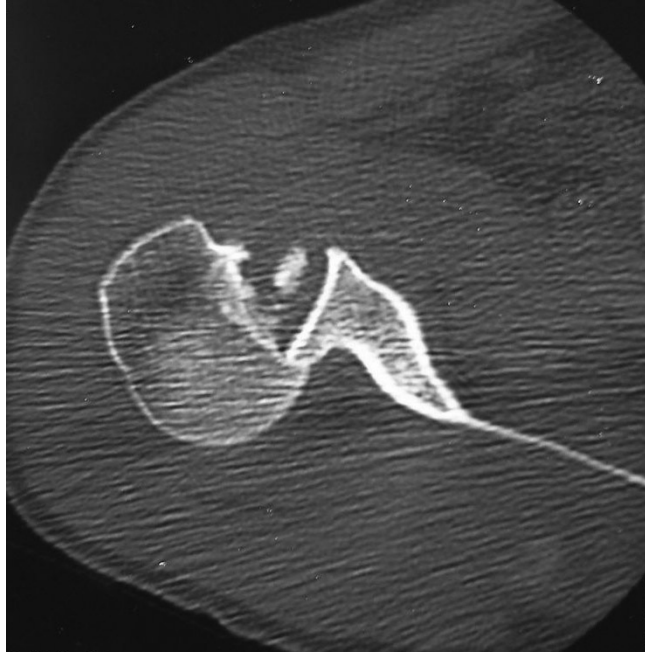


Fig. 2. Reverse Hill Sachs lesion can easily be seen

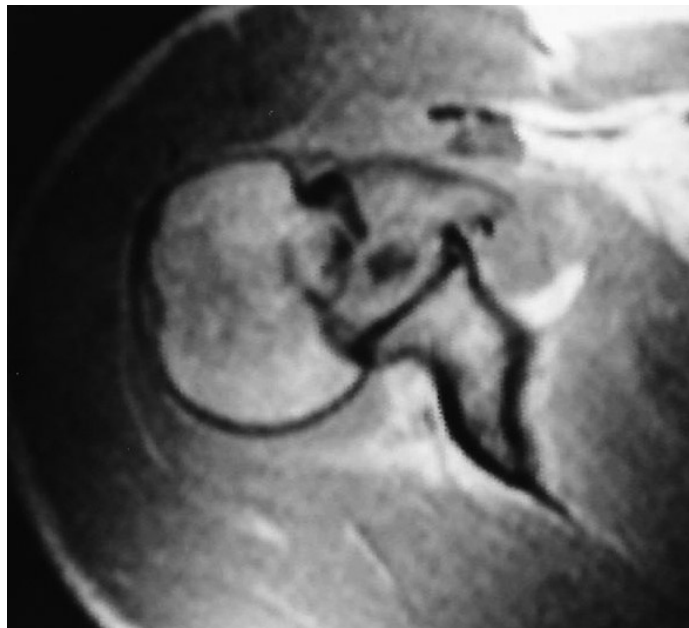

Fig. 3. Bone marrow edema and discontinuity of anterior capsule on MRI

A suction drain was inserted into the operation site before the incision was closed. The upper extremity was immobilized with a Velpau bandage.

The suction drain was removed 2 days after surgery. Then intensive active and passive rehabilitation program was encouraged. The last follow-up examination was carried out 40 months after operation.

The patient was pain free at the last visit. His shoulder joint ROMs were determined as follows: abduction 150°, adduction 40°, flexion 110°, exten-

sion 60°, internal rotation 90°, and external rotation 80° (Figure 5). All muscle strengths around the shoulder were 5/5. There was no neurologic deficit. Constant's functional score of the joint was 88 points [10]. Filling of the impression side and a better gleno-humeral relationship in comparison with pre-operative CTs were seen in the last visit CT scan (Figure 6). There was moderate arthrosis of the gleno-humeral joint.

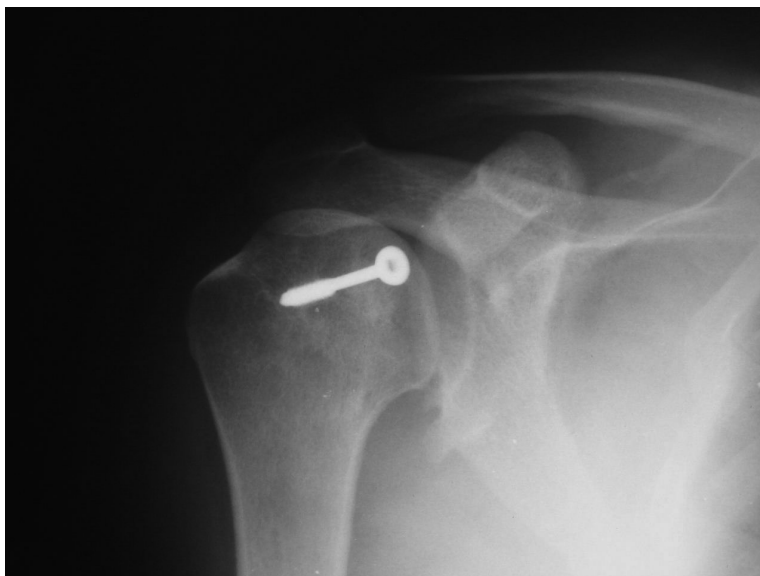


Fig. 4. Postoperative X-ray 40 months later

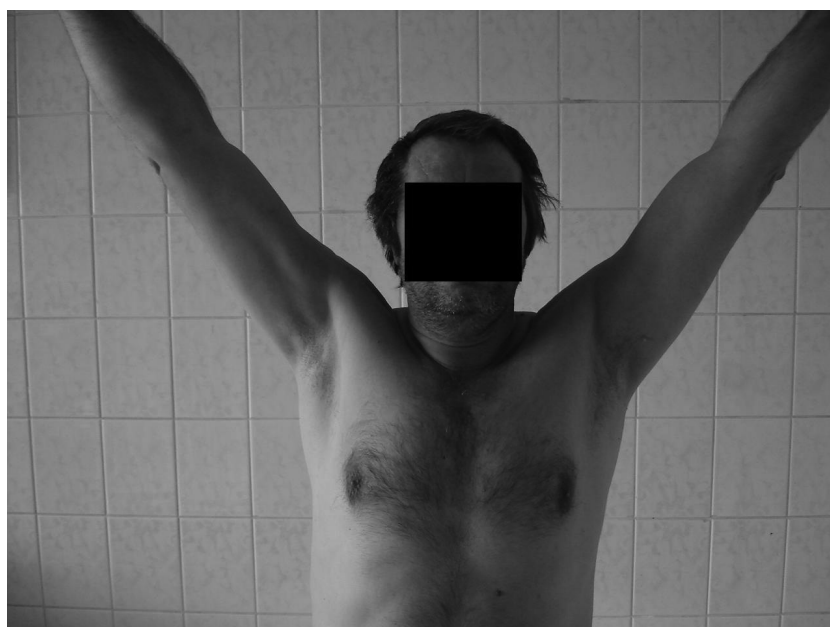

Fig. 5. The patient was satisfied with the clinical outcome at the last follow-up visit

DISCUSSION

Posterior shoulder dislocation is rarely seen injury secondary to high energy trauma. However, the diagnosis is difficult due to many traps for the inexperienced physician. Dubousset claimed that diagnosis of posterior dislocation cannot be based on radiographs alone [11]. Although the antero-posterior radiograph comprises some clues, it can easily be accepted as normal. Therefore an axillary view of the shoulder joint is very useful for precise diagnosis [9]. Aparicio et al. reported that axillary radiographs may not be taken because of extensive pain and restriction of ROM [8]. Garth et al. suggested that an apical

oblique X-ray may be helpful [12]. Wadlington et al. pointed out that a CT scan shows the humerus-glenoid relationship, impression fracture, and periarticular fractures but not a definitive diagnosis [13].

Cicak pointed that the extent of impression fracture, dislocation duration, patient's age, and activity level must be considered in the treatment planning [1]. An impression fracture is classified as small (less than 25% of articular surface), medium (25 - 50%), or large (more than 50%). Closed reduction is recommended in cases of small impression and duration shorter than 3 weeks [1]. Hawkins et al. reported that closed reduction was not possible in cases of more

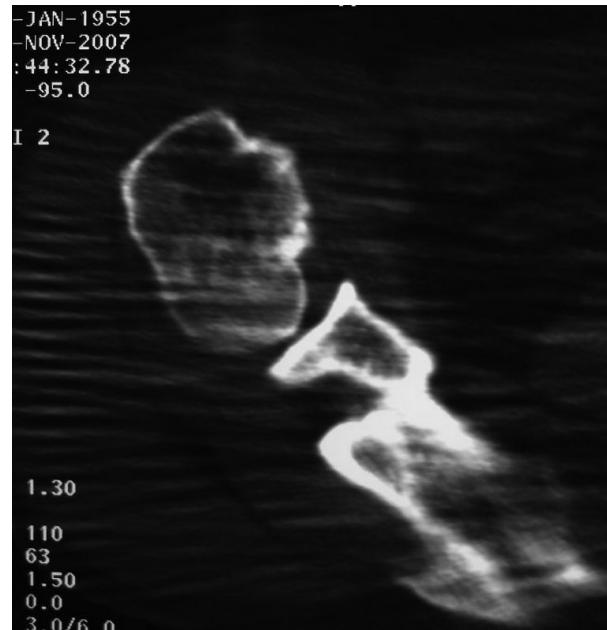


Fig. 6. It was clearly seen that the impression fracture side was filled with a bone bloc

than 3 weeks duration [2]. Open reduction and subscapularis tendon transfer described by McLaughlin is recommended when a closed reduction attempt has failed [5]. Medium size impression fractures can be managed by a McLaughlin or modified McLaughlin procedure as defined by Hughes and Neer [14]. Rotational osteotomy of the humeral head or reconstruction with a graft is an alternative [4, 6]. Arthroplasty is used when the impression fracture exceeds 50% [15].

We could not obtain an axillary X-ray due to pain and restriction of abduction. The extent of the impression fracture was about 25% on CT images. Therefore a transfer was planned of the subscapularis tendon with a bone block from the tuberculum minus to the impression side. We observed an improved humerus-glenoid relationship and filling of the impression side to a near-spherical shape in CT scans taken 40 months later when compared with the pre-operative CT. We identified moderate arthrosis in the shoulder joint according to Samilson criteria [16]. The patient's Constant's functional score was satisfactory for daily activities undertaken by the patient.

REFERENCES

1. Cicak N. Aspects of current management. Posterior dislocation of the shoulder. *J Bone Joint Surg (Br)* 2004; 86: 324 – 32.
2. Hawkins RJ, Neer CS, Pianta RM, Mendoza FX. Locked Posterior dislocation of the shoulder. *J Bone Joint Surg (Am)* 1987; 69: 9 – 18.
3. Mimura T, Mori K, Matsusue Y, Tanaka N, Nishi Y, Kobayashi M. Closed reduction for traumatic Posterior dislocation of the shoulder using the 'lever principle': two case reports and a review of the literature. *J Orthop Surg* 2006; 14 (3): 336 – 9.
4. LeF Porteous MJ, Miller AJ. Humeral rotation osteotomy for chronic posterior dislocation of the shoulder. *J Bone Joint Surg (Br)* 1990; 72: 468 – 9.
5. McLaughlin HL. Posterior dislocation of the shoulder. *J Bone Joint Surg (Am)* 1952; 34: 584 – 90.
6. Assom M, Castoldi F, Rossi R, Blonna D, Rossi P. Humeral head impression fracture in acute posterior shoulder dislocation: new surgical technique. *Knee Surg Sports Traumatol Arthrosc* 2006; 14: 668 – 72.

7. Ozkan M, Gul O, Bacakoglu K, Ozcan C, Ekin A. Treatment of posterior locked fracture dislocation of the shoulder with hemiarthroplasty. *Acta Orthop Traum Turc* 2000; 34: 45 – 9.
8. Aparicio G, Calvo E, Bonilla L, Espejo L, Box R. Neglected traumatic Posterior dislocation of the shoulder: controversies on indications for treatment and new CT scan findings. *J Orthop Sci* 2000; 5: 37 – 42.
9. Bloom MH, Obata WG. Diagnosis of posterior dislocation of the shoulder with use of velpau axillary and angle – up roentgenographic views. *J Bone Joint Surg (Am)* 1967; 49: 943 – 9.
10. Constant CR, Murley AHG. A clinical method of functional assessment of the shoulder. *Clin Orthop Relat Res* 1987; 214: 160 – 4.
11. Dubousset J. Luxations postérieures de l'épaule. *Rev Chir Orthop* 1967; 53: 65 – 85.
12. Garth WP, Stapp CE, Ochs Ch W. Roentgenographic demonstration of instability of the shoulder: The apical oblique projection. *J Bone Joint Surg (Am)* 1984; 66: 1450 – 3.
13. Wadlington VR, Hendix RW, Rogers LF. Computed tomography of posterior fracture-dislocations of the shoulder: case reports. *J Trauma* 1992; 32: 113 – 5.
14. Hughes M, Neer CS II. Glenohumeral joint replacement and postoperative rehabilitation. *Phys Ther* 1975; 55: 850 – 8.
15. Pritchett JW, Clark JM. Prosthetic replacement for chronic unreduced dislocation of the shoulder. *Clin Orthop Relat Res* 1987; 216: 89 – 93.
16. Samilson RL, Prieto V. Dislocation arthropathy of the shoulder. *J Bone Joint Surg (Am)* 1983; 65: 456 – 60.

Liczba słów/Word count: 1764

Tabele/Tables: 0

Ryciny/Figures: 6

Piśmiennictwo/References: 16

Adres do korespondencji / Address for correspondence

Cemil Kayali, MD, PhD

6445 sokak No:10/4 35550, Karsiyaka / Izmir, Turkey;

tel: 0 232 4696969 / 1226, fax: 0 232 433 07 56, e-mail: cemilkayali@yahoo.com

Otrzymano / Received

25.08.2008 r.

Zaakceptowano / Accepted

19.01.2009 r.