

The Treatment of Wrist Fractures with Epibloc System

Alessandro Geraci^{1(A,E,D,F)}, Antonio Sanfilippo^{2(B,D)}, Michele D'Arienzo^{2(C)}

¹ Orthopaedic and Traumatology Department, Santa Maria del Prato Hospital, Feltre, Italy

² Orthopaedic and Traumatology Department, University of Palermo, Italy

SUMMARY

Background. Fractures of the distal extremity of the radius are the most common bone lesions of the superior extremity of the body, representing 17% of the fractures treated in First Aid facilities. The restoration of anatomical relationships in the radiocarpal joint is considered to be a prerequisite for good functional recovery. There are numerous methods of treatment of these fractures. The Epibloc system is a percutaneous endomedullary synthesis alternative to the plaster cast in wrist fracture treatment.

Material and methods. The authors describe their experience with 81 fractures (63 type A2-3 fractures and 18 type C1) of the wrist treated with the Epibloc System (ES). The results were evaluated clinically, functionally and radiographically on the 7th, 14th, 35th, 90th day. The Gartland and Werley score modified by Sarmiento was used for the functional assessment of the wrist injuries.

Results. Twenty-nine patients (35.8%) had excellent results, 43 (53.1%) had good results. Forty-seven of the patients (58%) had a ROM of 100% of normal, with a dorsiflexion-palmar flexion (DF-PF) arc of 120 degrees or more. Seven (8.6 %) of the patients developed Sudeck's osteodystrophy. A "very moderate" or "moderate" malunion was observed in 19 cases (23.4%)

Conclusions. 1. The ES is a surgical technique for the treatment of numerous wrist fractures. These fractures can result in excellent mobility as well as a low rate of complications and secondary loss of reduction. 2. This method enables early functional recovery with low incidence of rigidity and algodystrophy. 3. This technique is best indicated for AO type A2-3 and type C1. 4. The ES is inadequate for patients with severe osteopaenia and markedly comminuted intra-articular fractures.

Key words: distal radius fracture, wrist fracture, Epibloc system, percutaneous synthesis, percutaneous pinning

BACKGROUND

Fractures of the distal radius account for an estimated 17% of fractures seen acutely in the emergency department [1]. These injuries occur most commonly among elderly women with osteoporosis, typically because of a fall onto an outstretched hand. Younger patients may also sustain distal radius fractures, often caused by a high-energy mechanism. Many of these fractures are intra-articular [2,3]. While a large number of these fractures are managed non-operatively, the number of patients who undergo surgical management is considerable. There are various methods of treatment of these fractures, including open reduction and internal fixation (ORIF) with volar or dorsal plates and screws, non-spanning external fixation (NSEF), closed reduction and percutaneous pinning (CRPP), spanning external fixators or variations of each [4,5]. Functional outcomes after surgical management of distal radius fractures have been related to bony anatomy and the ability to maintain reduction until osseous healing [6,7]. We present our experience with the percutaneous Epibloc™ system (ES), developed in Italy for the treatment of distal meta-epiphyseal fractures of the radius [8]. The system is based upon the elasticity of pins which are inserted into the medullary cavity of the proximal radius and the distal epiphysis, which they cross. The patient is in the supine position with the arm resting on a flat surface. After a manual reduction of the fracture under fluoroscopic guidance, a small incision is made to insert the pins while taking care of subcutaneous tendinous structures. The pins are in-

serted into the epiphysis of the radius with a motorized tool on the radial and cubital sides, more precisely at the internal dorsal angle of the epiphysis and the radial edge of the styloid, slightly dorsal to the long-abductor and short-extensor tendons of the thumb following a hypothetical line aimed at the mechanical centre of the epiphysis. Two highly elastic, high-calibre steel pins (35 cm long and 2.5 mm in diameter) are supported proximally in the medullary cavity of the radius. The tips of the pins are half-round on one side, so the distal epiphysis can be pierced and the medullary canal penetrated, allowing the pins to be advanced internally without penetrating the second cortical layer. This procedure is possible once the tip has been turned under fluoroscopic guidance, so that the half-round side can slide along the internal cortex of the diaphyseal canal. Distal support is found where the pins cross the epiphysis in a direction which will orient the elastic pressure produced by the pins. The system is stabilized by a small external plate where each pin is tightened with two screws (Fig 1). Two orthogonal folds are made in each pin with a clamp, and then the pins are attached to the plate pulling them apart from one another under fluoroscopic guidance, to compress the fragments of the fracture (Fig. 2). The elasticity of the pins results in a movement that pushes down and outwards which tends to bring the fragments in contact with one another and to create transversal ligament tension (ligamentotaxis), realigning the articular arch. The tension of the fibroperiosteal membrane simultaneously produces metaphyseal remodelling.

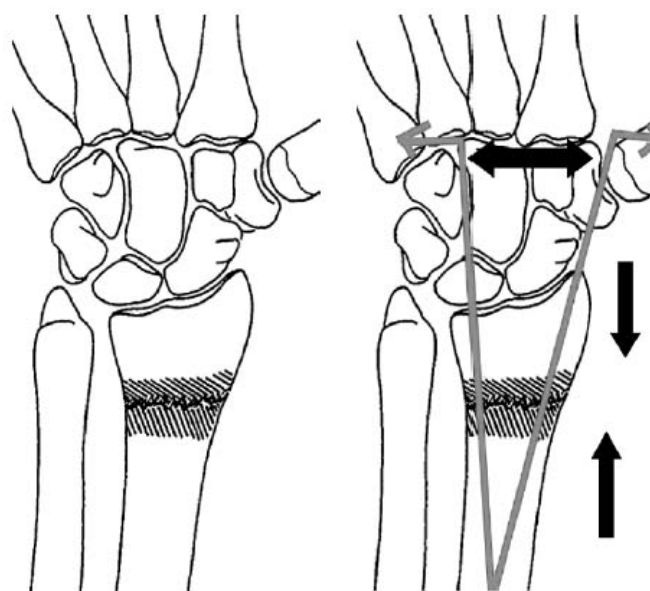


Fig. 1. Drawing of Epibloc System

MATERIALS AND METHODS

ES was performed in 81 patients with distal radial fractures at the Department of Orthopaedic Surgery of the University of Palermo between May 2006 and December 2008. There were 46 (56.8%) males

and 35 (43.2%) females in the group, with a mean age of 44.1 years (24-69). 64% of the fractures were on the dominant side (Tab. 1). Fractures were classified according to the AO classification system (Fig. 3). There were 63 closed extra-articular type A2-A3

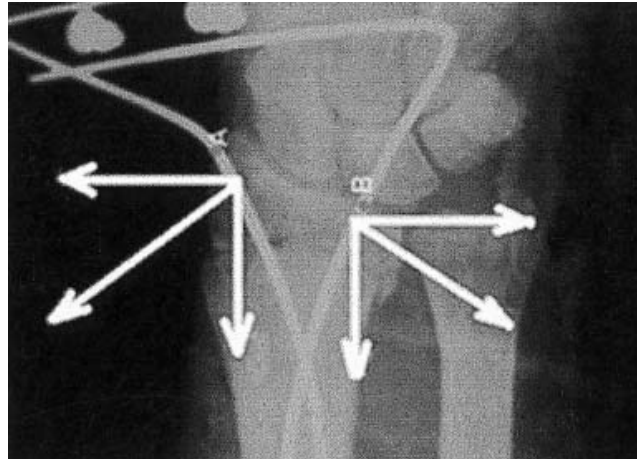


Fig. 2. The elastic-dynamic Epibloc system, the forces of distraction break down into compacting forces

Tab. 1. Epidemiology Study Group

| Wrist Fracture | A2/A3 | C1 |
|-----------------|-------|----|
| Number Patients | 63 | 18 |
| Mean Age | 44.1 | |
| Male/Female | 46/35 | |

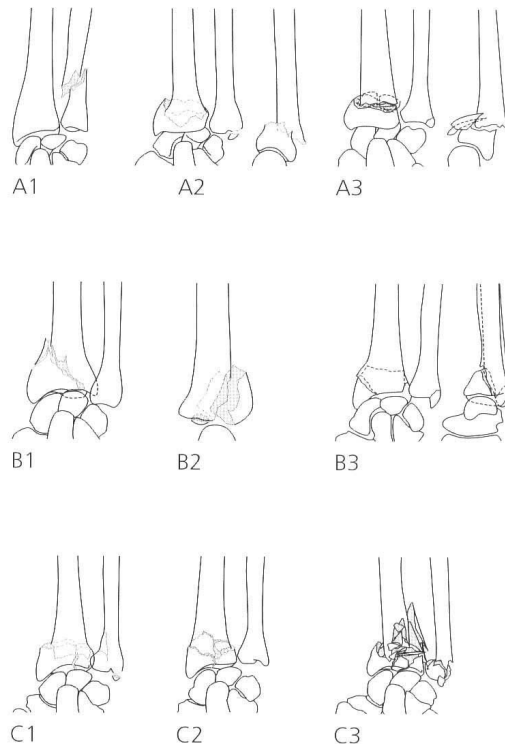


Fig. 3. A.O. Classification System of wrist fractures

fractures (including 51 dorsal displacements and 12 palmar displacements) (Fig. 4) and 18 type C1 slightly comminuted intra-articular fractures (Fig. 5). Severely comminuted intra-articular fractures and Barton's fractures were not included in this study. Eleven patients underwent primary treatment with a cast after bloodless reduction; the time between initial injury and operation ranged from 1 to 9 days (mean, 2.3 days). Active mobilization of the wrist was given immediately. Postoperative management included the following: clinical follow-up assessment and X-ray on day 7 (D7), bandage and clinical follow-up assessment on D14 and D28; X-ray and removal of

osteosynthetic material on D35; clinical assessment and X-ray on D90; and clinical assessment on D180. Physical therapy was necessary in 34 cases (41.9%). The programme included active and passive finger range of motion, hand and wrist oedema control, and active wrist motion exercises. The Gartland and Werley score modified by Sarmiento [9] was used for the functional assessment of the wrist injuries. This system is based on a demerit point system which involves an objective evaluation of wrist function (Fig. 6). Depending on the number of points scored, the outcome is classified as excellent, good or poor. Radiographic results were grouped into anatomical results

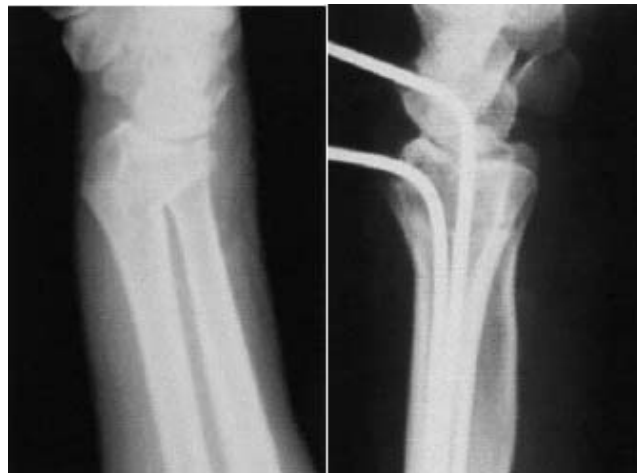

Fig. 4. A2 fracture of wrist treated with Epibloc System

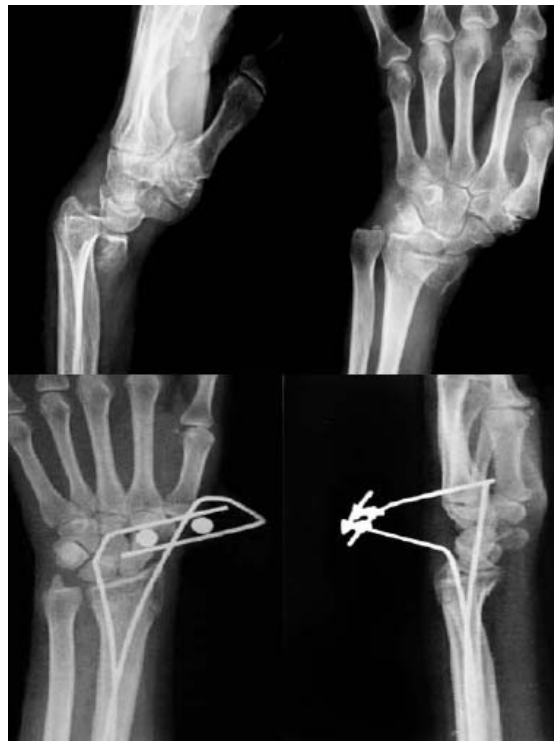

Fig. 5. C1 fracture of wrist treated with Epibloc System

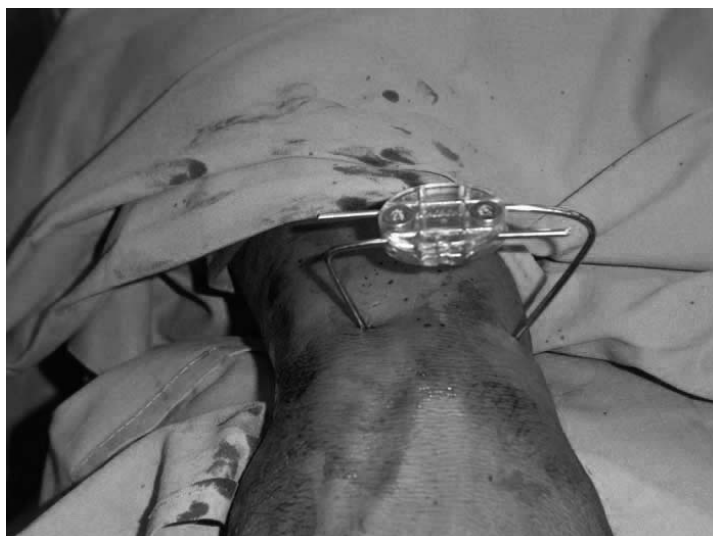

Fig. 6. The system is stabilized by a small external plate where each pin is tightened with two screws

and malunions according to the SOFCOT 2000 symposium [10].

RESULTS

The Epibloc system is shown to be simple in execution, minimally aggressive and quite steady. No tendinous, neurological or arterial iatrogenic lesions were reported from insertion of the pins.

The results were evaluated clinically, functionally and radiographically. All the patients had pain for a few days (range 1-4 days) that was controlled with oral analgesics. One (1.2%) of the 81 patients was lost to follow-up after the first-month assessment. Seventy-one (87.6%) patients tolerated the percutaneous fixator well. Two patients (2.5%) developed superficial pin site infection which was treated with better pin site care and an antibiotic. Osteomyelitis did not occur in any of the cases. Seven (8.6 %) of the patients developed Sudeck's osteodystrophy. Four patients (4.9%) developed carpal tunnel syndrome. Eleven (13.5%) had some form of residual deformity: Nine had a residual dorsal tilt of the distal radius

and two showed a degree of radial deviation. In a subjective evaluation, on a scale of 0 to 6 (0 being an excellent result as perceived by the patient with a painless and fully functional wrist), the average score was 2.5. A "very moderate" or "moderate" malunion was observed in 19 cases (23.4%). That was due to incomplete anatomical manual reduction rather than secondary loss of reduction. Three patients (with AO type C1 fractures) had loss of reduction in the early post-operative period and required open reduction and volar plate fixation (3.7%); the bone was severely porous in five cases. No patient developed a pseudoarthrosis (Tab. 2). The range of motion was assessed using a goniometer. Forty-seven patients (58%) had a ROM of 100% of normal, with a dorsiflexion-palmar flexion (DF-PF) arc of 120 degrees or more, 24 patients (29.6%) had a ROM of 75-99% of normal, with a DF-PF arc of 91-119 degrees, 6 patients (8.6%) had a ROM of 50-74% of normal with a DF-PF arc of 61-90 degrees, and 4 patients (4.9%) had a poor ROM. Using the modified Gartland and Werley demerit scoring system, the average score was

Tab. 2. Percentages of early complications in the study group

| Complications | Number of patients (%) |
|--------------------------------|------------------------|
| Superficial pin site infection | 2 (2.5%) |
| Osteomyelitis | 0 |
| Sudeck's osteodystrophy | 7 (8.6%) |
| Carpal tunnel syndrome | 4 (4.9%) |
| Residual deformity | 11 (13.5%) |
| Malunion | 19 (23.4%) |
| Deficit of movement | 4 (4.9%) |
| Loss of reduction | 3 (3.7%) |

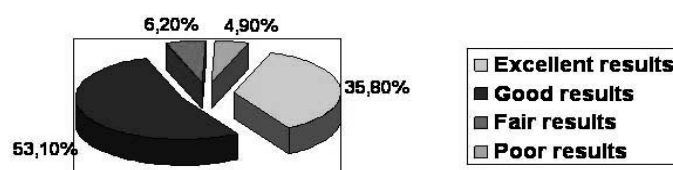


Fig. 7. Gartland and Werley demerit scoring system

7.22 (range 1-18); there were 29 patients (35.8%) who had excellent results, 43 (53.1%) patients who had good results, 5 patients (6.2%) with fair results, and four (4.9%) with poor results (Fig. 7).

DISCUSSION

Fractures of the distal end of the radius should be treated on the same principles as any other fracture near or involving a joint. Extra-articular fractures require as careful consideration as intra-articular fractures because malunion changes the carpal architecture, producing midcarpal instability, alteration in load distribution which may lead to a prearthritic state, and incongruence of the distal radio-ulnar joint. If the anatomical reduction is not obtained, mechanical failure may occur in the distal radioulnar joint and intercarpal joint. More than 20 degrees' angulation may cause concentric loading on the scaphoid and lunate fossae and the contact area may extend further dorsally compared to a normal wrist joint. 6-8 mm of radial shortening may cause ulnocarpal friction [11]. In the treatment of distal radial fractures, high quality reduction and safe preservation of the reduction until the fracture heals are mandatory to achieve a good result. The quality of reduction will be determined by comparing the palmar slope angle, radial inclination angle and radial length with the respective reference values [12]. The restoration of anatomical relationships in the radiocarpal joint is considered to be a prerequisite for good functional recovery. There are various methods of treatment of these fractures [13]: conservative treatment with cast braces, closed reduction and percutaneous fixation and casting, external fixation, open reduction and internal fixation with plates, a hybrid system. Treatment by manual reduction and percutaneous pinning can result in excellent mobility as well as a low rate of complications and secondary loss of reduction. It has the advantages of other percutaneous systems: no tissue adhesions or cutaneous scars, no exposure of the fracture site, and preservation of the haematoma,

which is considered the primary element in the development of a fracture callus [14]. The Epibloc System is a percutaneous endomedullary osteosynthesis system for use in wrist fracture treatment. This system is partially dynamic and compresses the fracture surfaces with transversal ligament tension, which helps maintain fracture reduction. In our study, excellent or good anatomical and functional results were obtained in 72 out of the 81 patients. The patients with type A2 fracture had excellent or good results, while the patients with type C1 fracture had poor results. In the literature, external fixation has been indicated when intra-articular comminution is present, while volar plate fixation with the use of either a locking plate or a neutralization plate has become increasingly popular among surgeons for the treatment of dorsally comminuted extra-articular distal radial fractures [15,16]. Our study clearly shows that extra-articular fractures were the best indication for clinical and anatomic success of the Epibloc system.

CONCLUSIONS

1. The ES is a surgical technique for the treatment of numerous wrist fractures. Treatment of these fractures by manual reduction and percutaneous pinning can result in excellent mobility as well as a low rate of complications and secondary loss of reduction.
2. The ES is apparently a valid alternative in fracture treatment of the distal radius, allowing the patient normal daily functioning. This method enables early functional recovery with a low incidence of rigidity and algodystrophy.
3. The ES of percutaneous endomedullary internal fixation is best indicated for AO type A2-3 extra-articular fractures of the distal radius and AO type C1 slightly comminuted articular fractures.
4. The ES is inadequate for patients with severe osteopaenia and markedly comminuted intra-articular fractures.

REFERENCES

1. Owen RA, Melton LJ III, Johnson KA, Ilstrup DM, Riggs BL. Incidence of Colles' fracture in a North American community. *Am J Pub Health* 1982; 72:605-607.
2. Affram PA, Bauer GC. Epidemiology of fractures of the forearm. A biomechanical investigation of bone strength. *J Bone Joint Surg Am* 1962;44-A:105-14.
3. Leung KS, Shen WY, Tsang HK, et al. An effective treatment of comminuted fractures of the distal radius. *J Hand Surg Am* 1990;15:11-7.
4. Bradway JK, Amadio PC, Cooney WP. Open reduction and internal fixation of displaced, comminuted intra-articular fractures of the distal end of the radius. *J Bone Joint Surg Am* 1989;71:839-47.
5. Ruch DS, Weiland AJ, Wolfe SW, et al. Current concepts in the treatment of distal radial fractures. *Instr Course Lect* 2004;53:389-401.
6. Ark J, Jupiter JB. The rationale for precise management of distal radius fractures. *Orthop Clin North Am* 1993;24:205-10.
7. Wagner WF Jr, Tencer AF, Kiser P, et al. Effects of intra-articular distal radius depression on wrist joint contact characteristics. *J Hand Surg Am* 1996;21:554-60.
8. D.S. Poggi and L. Figlini, Fratture semplici e complesse di polso trattate con sistema Epibloc™, *Riv Chir Mano* 1994;31(1): 95-101.
9. Sarmiento A., Pratt GW, Berry NC, Sinclair. Colles fracture functional bracing in supination. *Bone and Joint Surg* 57-A:311-317, 1975.
10. Symposium SOFCOT, réunion annuelle, nov. 2000. Les fractures fraîches du radius distal chez l'adulte. *Rev Chir Orthop* 2001;87(S 5):67-141.
11. Naidu SH, Capo JT, Moulton M, Ciccone W II, Radin A. Percutaneous pinning of distal radius fractures: a biomechanical study. *J Hand Surg [Am]* 1997;22:252-7.
12. Zyluk A, Puchalski P, Walaszek I, Janowski P. A reasonable algorithm for treatment of distal radius fractures. *Chir narzadow Ruchu Ortop Pol.* 2010; 75(1):10-6.
13. Koshkin AB, Sergeev SV, Matveev VS, Grishanin OB. Distal forearm fractures: the analytical approach for treatment. *Ortop Traumatol Reahabil.* 2008;10(4):324-30.
14. A. Ozaki, M. Tsunda and S. Kinohita, Role of fracture hematoma and periosteum during fracture healing in rats: interaction of fracture hematoma and the periosteum in the initial step of the healing process, *J Orthop Sci.* 2000;5(1): 64-70.
15. Willis AA, Kutsumi K, Zobitz ME, Cooney WP 3rd. Internal fixation of dorsally displaced fractures of the distal part of the radius. A biomechanical analysis of volar plate fracture stability. *J Bone Joint Surg Am.* 2006;88(11):2411-7.
16. Glickel SZ, Catalano LW, Raia FJ, Barron OA, Grabow R, Chia B: Long-term outcomes of closed reduction and percutaneous pinning for the treatment of distal radius fractures. *J Hand Surg (Am).* 2008;33(10):1700-5.

Liczba słów/Word count: 2542

Tabele/Tables: 2

Ryciny/Figures: 7

Piśmiennictwo/References: 16

Adres do korespondencji / Address for correspondence

Dr. Alessandro Geraci

Via Montegrappa 18/C Feltre, Italy

Phone: +393284527728, e-mail: geracialessandro@libero.it

Otrzymano / Received

13.09.2010 r.

Zaakceptowano / Accepted

28.12.2010 r.

