

# Post-traumatic Heterotopic Ossification of The Crus. A Case Study

**Kalenderer Onder<sup>(A,B,,E,F)</sup>, Bozoglan Muhammed<sup>(E,F)</sup>, Unluoglu Saime<sup>(D,E)</sup>,  
Agus Haluk<sup>(E)</sup>**

İzmir Tepecik Training and Research Hospital, İzmir, Turkey

## SUMMARY

The formation of mature lamellar bone at an ectopic site in the body is called heterotopic ossification. We report the case of a 28 year-old patient with heterotopic ossification (HO) in the left crus. He complained of difficulties with walking and limited ROM of the ankle joint. At surgery, an incision was made through the center of the HO focus, which was palpable. No change in ROM of the ankle joint was observed following HO removal. The decision was made to lengthen the Achilles tendon. After the lengthening of the Achilles tendon, the ROM of the ankle joint was increased. Lengthening of the Achilles tendon following the removal of post-traumatic HO in the crus is a safe and effective procedure; if the ROM of the ankle joint is restricted.

**Key words:** Heterotopic ossification, Myositis ossificans, Trauma

## BACKGROUND

The formation of mature lamellar bone at an ectopic site in the body is called heterotopic ossification (HO) [1,2]. The pathogenesis of HO is not clearly defined [3]. HO is found mainly in muscles; however, histopathologically identical lesions have been demonstrated in tendons, subcutaneous fat, ligaments, fasciae, aponeuroses, and joint capsules [4]. The proximity of a HO focus to a joint may limit the movements of the joint and lead to many problems in performing activities of daily living, including pain [5]. Indications for surgical resection of HO are defined as pain and functional deficit in ROM with functional difficulties.

In this report, we present a case where an additional Achilles tendon lengthening procedure was performed to gain ROM during post-traumatic HO excision at the crus.

## CASE REPORT

A 28-year-old male with persistent discomfort in the left crus and decreased ROM of the ankle joint for eight years was admitted to our hospital. He complained of difficulties while walking and problems with other daily activities. There was a history of trauma nine years before; however, no predisposing factors such as head or burn injuries were documented.

A physical examination revealed a hard, approximately 8 cm bone-like mass located postero-medial-

ly in the proximal third of the crus. Moreover, there was another little structure in the proximal third of the crus located postero-laterally. The patient had an antalgic gait and muscular atrophy in the right thigh. The range of ankle motion was restricted to 0°-20°. Neurovascular examination was normal. No weakness during plantar flexion of the ankle was observed on manual muscle testing. He had a normal white blood cell count, and an erythrocyte sedimentation rate of 7 mm/hr. His serum alkaline phosphatase was within the normal range. A radiographic examination showed a well-outlined spindle-shaped ossifying mass (Figure). Computerized tomography of the left crus demonstrated an ossifying lesion at the proximal third.

At surgery, an incision was made through the center of the HO focus, which was palpable. The gastrocnemius muscle was divided longitudinally to allow access to the HO. Next, the HO was removed. However, no change in the ROM of the ankle joint was observed. For this reason, we decided that lengthening of the Achilles tendon was required. After the lengthening of Achilles tendon, the ROM of the ankle joint increased. At the end of the procedure a suction drain was used. A long leg cast was applied for six weeks. After the cast was removed, a short molded leg brace was used for three months.

Macroscopically, the lesion measured 7x5x1.5 cm and it was well circumscribed. It was gray-yellow and firm with a rough granular surface showing hem-

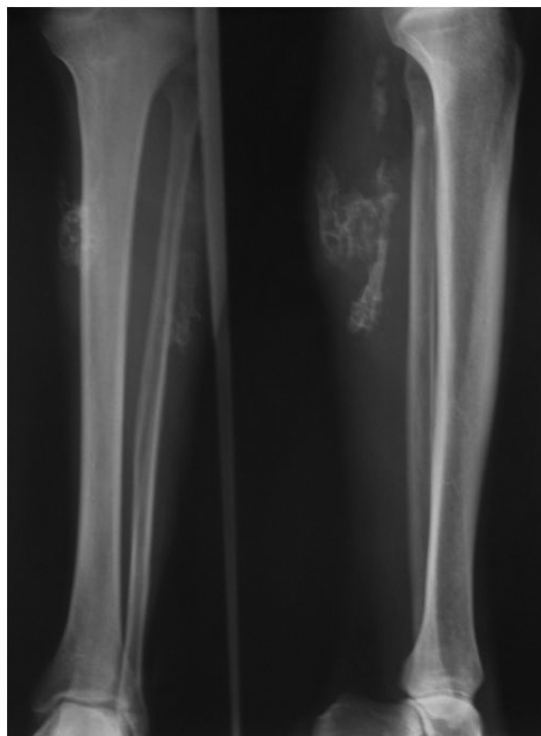


Fig. 1. Radiological appearance of heterotopic ossification

orrhagic areas surrounded by different amounts of ossification, muscle, and adipose tissue. Microscopically, lesion was composed of mature lamellar bone, osteoid, and striated muscle fibers admixed with mature adipose tissue and muscular structures.

After 36 months of follow-up, significant improvements in pain and ambulatory functions were observed. Furthermore, an enhanced range of motion of the ankle joint was also noted. No clinical and radiological recurrence was detected.

## DISCUSSION

HO could be defined as the formation of bone in tissues which normally exhibit no properties of ossification [6]. HO has been shown to be associated with many predisposing factors including neurological injury (both to the spinal cord and to the brain), major joint surgery, and burns [6].

Post-traumatic HO typically occurs around the hip, knee, and elbow when associated with significant soft tissue injury [3]. In our case, HO was observed secondary to a soft tissue injury in the posterior part of the crus.

There are few data regarding the excision of HO of the crus. In our case, since no increase in the ROM of the ankle joint was observed after the excision of HO, an additional Achilles tendon lengthening pro-

cedure by Z-plasty was performed. ROM of the ankle joint improved postoperatively and ambulatory and sitting functions were improved as the result of our treatment.

Fuller et al. reported 17 consecutive patients with neurological injuries (22 knees). The authors described the removal of HO of the knee as a valuable procedure in these patients. However, after resection of HO, they performed associated lower extremity procedures, including lengthening of tendons, in 10 of these 17 patients [5].

Prophylaxis against recurrence of HO is controversial [6]. Indomethacin, meloxicam, bisphosphonates (especially etidronate), and radiotherapy have been used successfully to prevent HO. No prophylactic drugs were used in our patient and no evidence of recurrent HO was observed on follow-up radiographs.

## CONCLUSION

The basic principle in the management of post-traumatic HO is surgical excision of the mass. However, when ROM is not corrected sufficiently, additional lengthening surgery of the tendons is required. A lengthening procedure is a safe and effective method following the removal of HO.

## REFERENCES

1. O'Connor JP. Animal models of heterotopic ossification. *Clin Orthop* 1998; 346:71-80.
2. Kaplan FS, Glaser DL, Hebela N, Shore EM. Heterotopic ossification. *J Am Acad Orthop Surg*, 2004; 12(2): 116-125.
3. Specht LM, Gupta S, Egol KA, Koval KJ. Heterotopic ossification of the quadriceps following distal femoral traction. A report of three cases and a review of the literature. *J Orthop Trauma* 2004; 18: 241-246.
4. Enzinger FM, Weiss SW. Osseous soft tissue tumors. In: Enzinger FM, Weiss Sw, editors. *Soft tissue tumors*. 3 rd ed. St. Louis: Mosby, 1995 p: 1013-37.
5. Fuller DA, Mark A, Keenan MAE. Excision of heterotopic ossification from the knee. A functional outcome study. *Clin Orthop* 2005; 438: 197-203.
6. Pape HC, Marsh S, Morley JR, Krettek C, Giannoudis PV. Current concepts in the development of heterotopic ossification. *J Bone Joint Surg (Br)* 2004; 86-B: 783-787.

Liczba słów/Word count: 1105

Tabele/Tables: 0

Ryciny/Figures: 1

Piśmiennictwo/References: 6

Adres do korespondencji / Address for correspondence

Onder Kalenderer

1843/2 sokak No: 67/7 Gultekin apt, 35530, Karsiyaka, Izmir, Turkey

Tel: +90 532 297 10 67, Fax: + 90 232 433 07 56, e-mail: okalenderer@yahoo.com

Otrzymano / Received

28.14.2010 r.

Zaakceptowano / Accepted

14.02.2011 r.

