

# The Use of Computer Navigation in Hip Arthroplasty: Literature Review and Evidence Today

Shahid Punwar<sup>1(A,B,D,E,F)</sup>, Wasim S. Khan<sup>1(A,B,D,E,F)</sup>, Umile Giuseppe Longo<sup>2(B,E,F)</sup>

<sup>1</sup> University College London Institute of Orthopaedic and Musculoskeletal Sciences, Royal National Orthopaedic Hospital, Stanmore, Middlesex, UK

<sup>2</sup> Royal Free Hospital, Department of Trauma & Orthopaedics, Royal Free Hampstead NHS Trust, London, UK

## SUMMARY

Total hip replacement arthroplasty and hip resurfacing are two of the most successful orthopaedic operations performed worldwide. Critical to the success of these operations is the accurate placement of the components. Correct component alignment reduces mechanical wear and the risk of dislocation. Traditionally, correct component alignment relies on the surgeon referencing from the position of the patient on the table and anatomical landmarks. However, it is now known that this leads to a wide variability in component position. Computer navigation systems aim to optimise component placement. The purpose of this review is to describe the different types of computer navigation systems available and their use in both total hip arthroplasty and hip resurfacing.

**Key words:** hip, arthroplasty, computer, navigation

## INTRODUCTION

Hip arthritis is a major cause of disability worldwide [1,2]. In the United States more than 200,000 total hip replacements are performed annually, a figure set to rise as the population ages. Key to success is accurate alignment of the components as a poorly aligned acetabular cup increases the risk of dislocation, reduces the range of motion and can also accelerate component wear, leading to early prosthesis failure [3].

It is also now known that the measurement of acetabular component position from plain radiographs can be inaccurate [4]. Orthopaedic procedures dealing with a non-deformable tissue such as bone are suitable for computerised guidance based on preoperatively and intraoperatively obtained images. Current uses of computerised navigation in total hip arthroplasty include proper placement of the acetabular component, measurement of limb-length changes, enablement of minimally invasive surgery and proper placement of components for hip resurfacing procedures [5].

## TYPES OF COMPUTER NAVIGATION SYSTEMS

Computer navigation systems have been in use in hip arthroplasty since 1992 [6,7]. The imaging systems that are used during computer assisted surgery can be divided into image-based and imageless systems. Image-based systems require the collection of morphological information by preoperative computer-

ised tomography (CT) or magnetic resonance imaging (MRI) scans, or by means of intraoperative fluoroscopy as shown in Figure 1. Imageless systems use a virtual anatomical model which is embedded in the software and is supplemented by intraoperative registration data of anatomical landmarks [8]. Imageless systems appear to be the most popular systems in clinical use judging by our experience and the published literature on navigation. These systems are based on virtual images as shown in Figure 2.

## COMPUTER NAVIGATION IN TOTAL HIP ARTHROPLASTY

Hip arthroplasty is suited to computer navigation as specific targets for component positioning have been defined. The orientation of the acetabular component is probably the most important factor in successful hip arthroplasty, and it is therefore not surprising that computer navigated acetabular positioning has received the most attention in the literature. Lewinnek et al (1978) defined a 'safe zone' for acetabular cup positioning of 5-25 degrees of anteversion and 30-50 degrees of inclination [9]. Components positioned outside this range were approximately four times more likely to dislocate. Although the study by Lewinnek et al was based on only nine dislocations, Biedermann et al (2005) showed similar results in their series of 127 dislocations [9,10].

Most surgeons use intraoperative alignment jigs to place the acetabular component referencing of the

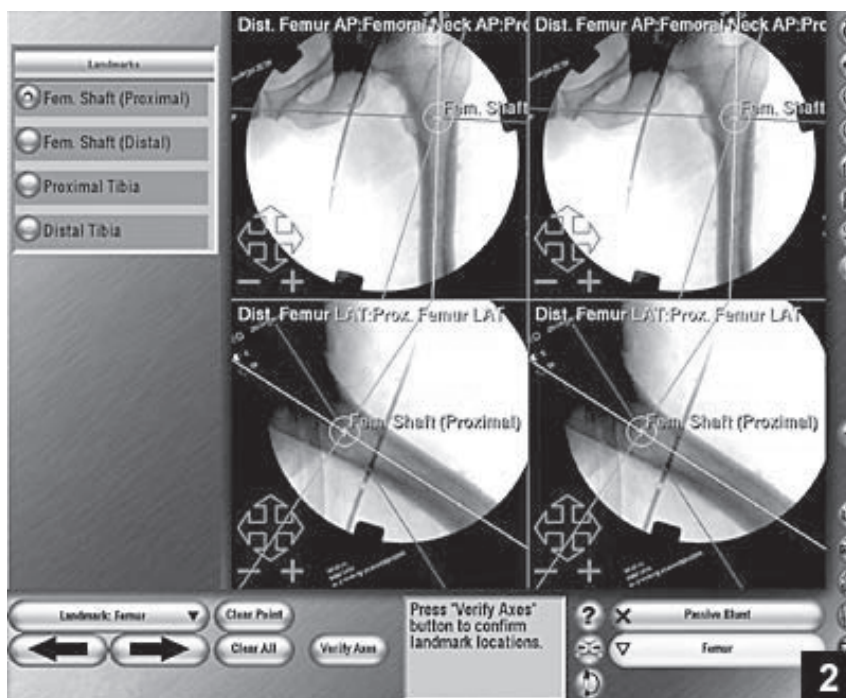


Fig. 1. Intraoperative fluoroscopic navigation

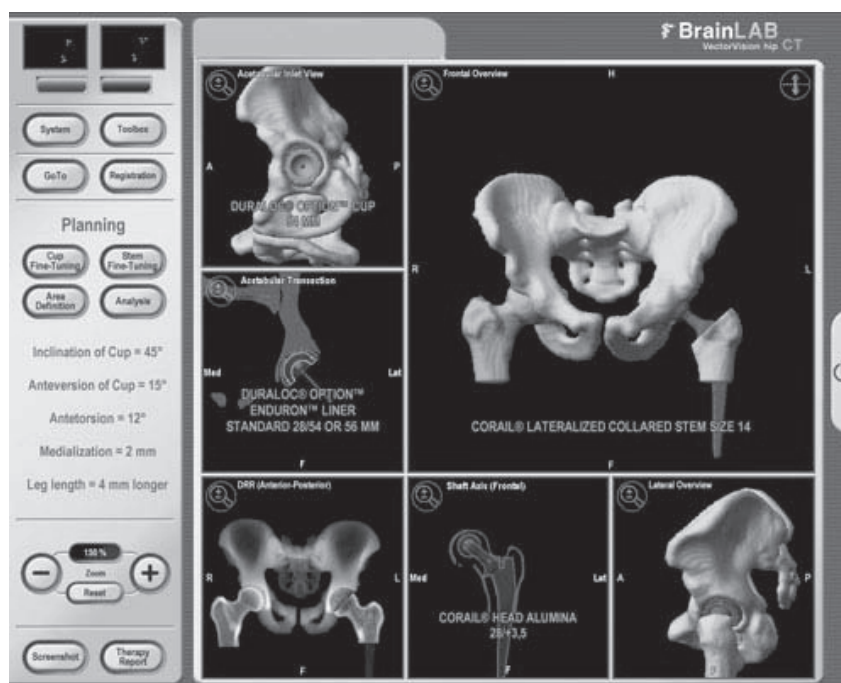


Fig. 2. Virtual image of patient's pelvis for imageless navigation

position of the patient on the operating table. In the lateral position, vertical orientation of the cup is usually judged from the floor, and anteversion from the patient's superior shoulder [11]. However, it is now known that the exact position of the patient's pelvis on the table is difficult to judge. The surgeon should not assume that the orientation of the pelvis is in line with the table or the patient's body. In the lateral position, the lumbar lordotic curve flattens and the pelvis may be flexed forward as much as 35 degrees [12]. In addition the superior aspect of the acetabulum may be tilted towards the foot of the table by 10-15 degrees. This means that cups placed with alignment jigs may actually be excessively retroverted and too vertical.

Digioia et al (2002) further demonstrated the high variability of mechanical acetabular alignment guides in the lateral position [13]. They found significant variability in pelvic orientation resulting in unacceptable alignment in 78% of acetabular components that had been placed with mechanical alignment guides.

Computer-assisted navigation of the acetabular component first requires registration of anatomical landmarks so that the computer can determine where the pelvis lies in space [14]. This is usually done by registering the anterior superior iliac spines and the pubic tubercle. By referencing these landmarks, the anterior pelvic plane is created, which is used for referencing cup position [15]. For imageless systems,

registration is accomplished with optical trackers mounted to the pelvis as shown in Figure 3. An optical pointer is then used to register the anterior superior iliac spines and the pubic tubercle either through small incisions or simply by palpation and then registration of the soft tissue directly over the anatomical landmark [16]. For imageless systems, the registration part of the process is usually done while the patient is supine in order to access the opposite anterior superior iliac spine. The patient can then be turned to the lateral decubitus position, which can be a problem when there is an optical tracker mounted to the pelvis [17].

The transverse acetabular ligament has also been used as a reference point to assist in determining the true version plane of the acetabulum. The transverse acetabular ligament is the part of the acetabular labrum that bridges the acetabular notch and is often used as a reference point for cup version by surgeons using a freehand technique. When the transverse acetabular ligament is registered along with the superior aspect of the acetabulum, the result is the creation of a true acetabular inlet plane. Kelley and Swank (2009) found that by using this method 82% of the acetabular components were placed within the abduction safe zone and 71% were placed within the anteversion safe zone as defined by Lewinnek [18]. In a recent systematic review and meta-analysis looking at 400 patients, although mean cup inclination and anteversion were not statistically significantly differ-

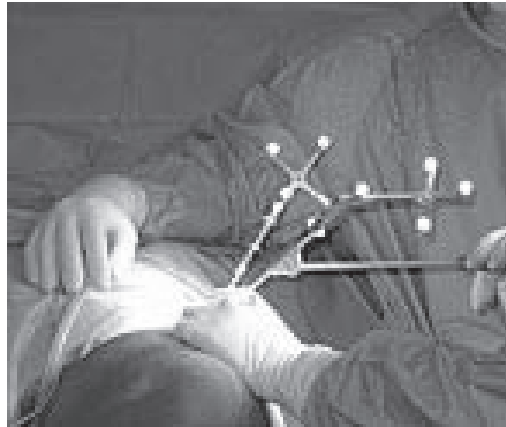


Fig. 3. Optical trackers mounted on patient's pelvis

ent between the conventional groups and the navigated groups, navigation reduced the variability in cup positioning and the risk of placing the acetabular component beyond the safe zone [19]. This review suggests that, based on the current literature, navigation is a reliable tool to optimize cup placement, and to minimize outliers. However, long-term outcomes and cost utility analyses are needed before conclusive statements can be drawn about the value of routine navigation in THA.

Leg length discrepancy following total hip replacement can contribute to poor hip function. Abnormal gait, pain, neurological dysfunction and patient dissatisfaction have all been described as a result of leg length inequality. Manzotti et al (2009) showed that significantly better leg lengths could be achieved using a computer navigated system compared to freehand techniques [20]. However this study failed to show any significant difference in functional outcome between the two groups.

In THA the advantages of minimally-invasive surgery over classic techniques include decreased blood loss, less pain, faster recovery, shorter hospital stay and rehabilitation, and less scarring [21]. Minimally-invasive surgery would appear to be the ideal technique to utilize the accuracy of computerised navigation. The smaller operative field naturally makes component positioning more difficult by freehand techniques [22].

### COMPUTER NAVIGATION IN TOTAL HIP RESURFACING

The orientation of the acetabular component is probably the most important factor in successful hip resurfacing. It has recently been shown that increasing the inclination of the acetabular component above 55 degrees in hip resurfacing leads to an 'edge loading' effect with a much greater release of metal

ions [23,24]. Elevated serum metal ions have been associated with local pseudotumour formation and have unknown systemic effects which may include carcinogenic potential [25,26].

Hip resurfacing has gained popularity as a bone conserving alternative to total hip arthroplasty in the young and active adult with degenerative hip disease [27]. The larger head diameters offer greater postoperative stability and may decrease wear rates. However hip resurfacing is inherently more difficult to perform than traditional total hip arthroplasty because of the limited femoral resection which makes acetabular visualisation more difficult. Preparing the acetabulum prior to addressing the femoral head creates limitations in terms of exposure and mobilization of tissues, thus posing a technical challenge to the surgeon and increasing the risk of component malalignment [28].

Errors in component positioning during the surgeon learning curve are common in hip resurfacing. Navigation of the acetabular cup in hip resurfacing follows an identical procedure to total hip arthroplasty. Imageless navigation in hip resurfacing, as shown in Figure 4, has been shown to help avoid component malposition during the surgeon learning curve [29-31].

There is a unique risk of femoral neck fracture associated with hip resurfacing, with a prevalence reported to vary from 0% to 17% [32,33]. Among other factors, several studies have suggested that notching of the superolateral aspect of the femoral neck and varus placement of the femoral component increase the likelihood of femoral neck fracture [34,35]. Preparation of the femoral side is therefore an attractive target for computer guidance. The key step for navigated preparation of the femoral side is the guide wire insertion into the femoral head to determine implant orientation. On-line display of the actual wire posi-

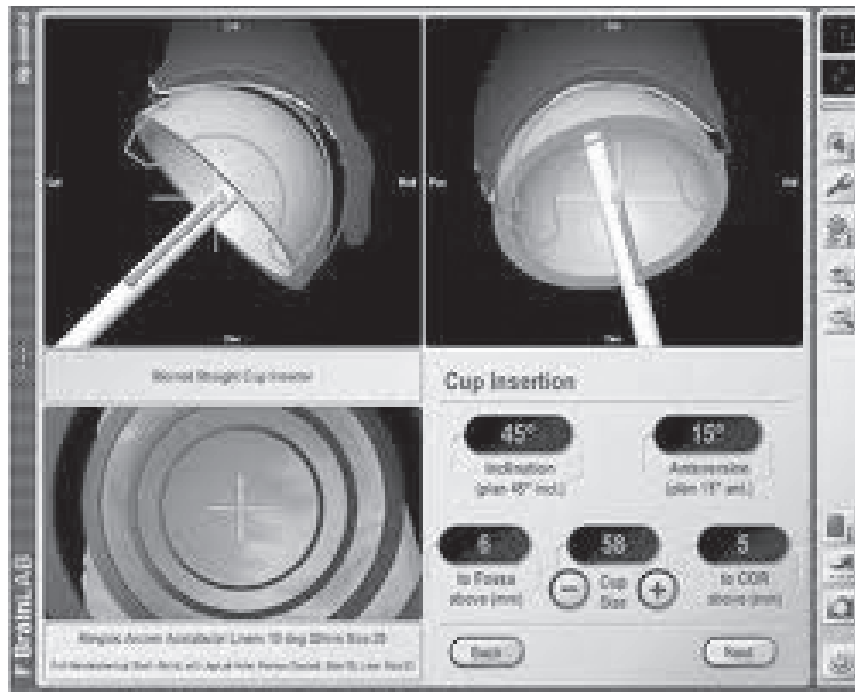


Fig. 4. Imageless navigation for femoral head preparation in hip resurfacing

tion in three dimensions allows for immediate correction and best match with the pre-planned pin alignment. The wire is then overdrilled and replaced by the instrumentation guide for femoral head preparation [36,37].

In a recent cadaveric study, computer navigation was found to be more accurate and more consistent in its placement of the femoral component than standard instrumentation [38,39]. The authors suggest that image-free computer-assisted navigation may have an application in aligning the femoral component during hip resurfacing. Studies using artificial bone models have shown greater accuracy and consistency in positioning the femoral head resurfacing component using computer navigation [40]. A recent clinical study looking at 37 hip resurfacing arthroplasties showed that the computer navigation system generates a reliable model of the proximal femur, allows accurate placement of the femoral component and provides precise measurement of implant alignment during hip resurfacing, thereby reducing the risk of component malpositioning and femoral neck notching [41].

Revision THA procedures present with a variable set of challenges and require individual planning and appropriate selection of approach and implants [42]. Intraoperative evaluation is very often required due to distorted surgical landmarks, lack of objective image analysis of prosthesis loosening and bone stock damage. These factors in turn determine the scope of

the procedure, selection of implants and need for grafts. It is likely that navigation will play a greater role in revision procedures as they become more common. Young patients with osteoarthritis secondary to the hip dysplasia also present additional challenges including previous surgeries including osteotomies of the acetabulum and femur, and altered neck-shaft angle [43]. Young patients with a high level of activity and expected life span are at a greater risk of prosthesis wear. This makes it even more important to ensure that prosthesis placement is optimum, enabling longevity of the implants.

#### WHY AREN'T COMPUTER NAVIGATION SYSTEMS IN WIDER USE?

There are still only a handful of randomised controlled trials, meta-analyses and systematic reviews that have been published on navigated hip arthroplasty [44-47]. The most consistent finding from these studies is that computer navigation improves the accuracy of acetabular cup positioning and minimises outliers in both total hip arthroplasty and hip resurfacing, just like it does for knee arthroplasty [48]. The accuracy of femoral component placement in hip resurfacing can also be improved with navigation and errors during the surgeon learning curve minimised [49].

Computer navigation is not a new concept or technology [50]. Its uptake has been slow due to various obstacles which include cost, increased operative

time and a general reluctance of the surgical community to accept navigation as a routine part of the arthroplasty process. Experienced surgeons can be reluctant to change tried and tested methods. However, there is substantial evidence that computerised systems can improve component positioning as compared with freehand techniques [51]. If we assume that optimal component positioning leads to better outcomes, it is logical to predict a resurgence in interest in computer navigated hip arthroplasty. The results of long-term clinical outcome studies comparing navigated against non-navigated hips are awaited. It is likely that surgical technique, which is an important factor in non-navigated THRs, will remain an important consideration if complications are to be avoided [52].

Computer navigation has the ability to improve the quality of prosthetic joint arthroplasty similar to the use of intraoperative fluoroscopy in fracture surgery. There are, however, various obstacles to performing computer-assisted surgery [53]. Additional equipment is needed in the operating theatre, which may have to be modified. A technician may also be needed specifically for the navigation equipment. The additional navigation steps throughout the procedure add time to the case, which can be important

from an anaesthetic point of view and also in terms of getting through the operating list. Surgical approach has to be considered carefully as imageless techniques require registration with the patient supine. The patient may then need to be re-positioned into the lateral decubitus position [54]. Personnel in the operating theatre need to think carefully about moving so as not to interrupt the line of sight of the sensors for imageless techniques. Both the additional equipment and the increase in operating time contribute to the extra cost of computer navigated surgery. Some studies have reported difficulty in accurately registering the pelvis using imageless navigation systems [55].

## CONCLUSION

Although there is proven improvement in the accuracy of component alignment with navigation, this has not been conclusively shown to translate to better functional results. The true benefit of computer navigated arthroplasty is likely to be in the reduction of wear and subsequent enhanced longevity of the prosthesis. Long-term studies with large numbers will be needed to demonstrate this. In addition, like any technology, navigation systems are not without faults.

## REFERENCES

1. Dheerendra S, Khan WS, Saeed MZ, Goddard NJ. Recent Developments in Total Hip Replacements: Cementation, Articulation, Minimal-Invasion and Navigation. *J Perioper Pract* 2010;20:133-8.
2. Eingartner C. Current trends in total hip arthroplasty. *Ortop Traumatol Rehabil* 2007;9:8-14.
3. Moskal JT, Capps SG. Improving the accuracy of acetabular component orientation: avoiding malposition. *J Am Acad Orthop Surg* 2010;18:286-96.
4. Kalteis T, Handel M, Herold T, Perlick L, Paetzel C, Grifka J. Position of the acetabular cup - accuracy of radiographic calculation compared to CT-based measurement. *Eur J Radiol* 2006;58:294-300.
5. Steppacher SD, Kowal JH, Murphy SB. Improving Cup Positioning Using a Mechanical Navigation Instrument. *Clin Orthop Relat Res*. 2010 Sep 18. [Epub ahead of print]
6. Bargar WJ. Robots in orthopaedic surgery: past, present and future. *Clin Orthop Rel Res* 2007;463:31-6.
7. Eingartner C. Current trends in total hip arthroplasty. *Ortop Traumatol Rehabil* 2007;9:8-14.
8. Olsen M, Chiu M, Gamble P, Boyle RA, Tumia N, Schemitsch EH. A comparison of conventional guidewire alignment jigs with imageless computer navigation in hip resurfacing arthroplasty. *J Bone Joint Surg* 2010;92A:1834-41.
9. Lewinnek GE, Lewis JL, Tarr R, Compere CL, Zimmerman JR. Dislocations after total hip-replacement arthroplasties. *J Bone Joint Surg* 1978;60A:217-20.
10. Biedermann R, Tonin A, Krismser M, Rachbauer F, Eibl G, Stockl B. Reducing the risk of dislocation after total hip arthroplasty: the effect of orientation of the acetabular component. *J Bone Joint Surg* 2005;87B:762-9.
11. Yamaguchi M, Akisue T, Bauer TW, Hashimoto Y. The spatial location of impingement in total hip arthroplasty. *J Arthroplasty* 2000;15:305-13.
12. McCollum DE, Gray WJ. Dislocation after total hip arthroplasty. Causes and prevention. *Clin Orthop Rel Res* 1990;261:159-70.
13. Digioia AM 3rd, Jamaraz B, Plakseychuk AY, Moody JE Jr, Nikou C, Labarca RS, Levison TJ, Picard F. Comparison of a mechanical acetabular alignment guide with computer placement of the socket. *J Arthroplasty* 2002;17:359-64.
14. Pitto RP, Malak S, Anderson IA. Accuracy of computer-assisted navigation for femoral head resurfacing decreases in hips with abnormal anatomy. *Clin Orthop Relat Res* 2009;467:2310-7.
15. Hasart O, Poeppelau BM, Asbach P, Perka C, Wassilew GI. Ultrasound-based navigation and 3D CT compared in acetabular cup position. *Orthopedics* 2009;32:6-10.
16. Legaye J. Influence of the sagittal balance of the spine on the anterior pelvic plane and on the acetabular orientation. *Int Orthop* 2009;33:1695-700.
17. Blondel B, Parratte S, Tropiano P, Pauly V, Aubaniac JM, Argenson JN. Pelvic tilt measurement before and after total hip arthroplasty. *Ortop Traumatol Surg Res* 2009;95:568-72.

18. Kelley TC, Swank ML. Role of navigation in total hip arthroplasty. *J Bone Joint Surg* 2009;91A:153-8.
19. Beckmann J, Stengel D, Tingart M, Götz J, Grifka J, Lüring C. Navigated cup implantation in hip arthroplasty. *Acta Orthop* 2009;80:538-44.
20. Manzotti A, Cerveri P, De Momi E, Pullen C, Confalonieri N. Does computer assisted surgery benefit leg length restoration in total hip replacement? Navigation versus conventional freehand. *Int Orthop*: 11 Nov 2009. [Epub ahead of print]
21. Wojciechowski P, Kusz D, Kopec K, Borowski M. Minimally invasive surgery in total hip arthroplasty. *Ortop Traumatol Rehabil* 2007;9:1-7.
22. Rubash HE, Pagnano MW. Navigation in total hip arthroplasty. *J Bone Joint Surg* 2009;91A (Suppl 5):17.
23. De Haan R, Campbell PA, Su EP, De Smet KA. Revision of metal-on-metal resurfacing of the hip: the influence of malpositioning of the components. *J Bone Joint Surg* 2008;90B:1158-63.
24. Langton DJ, Jameson SS, Joyce TJ, Webb J, Nargol AV. The effect of component size and orientation on the concentrations of metal ions after resurfacing arthroplasty of the hip. *J Bone Joint Surg* 2008;90B:1143-51.
25. Grammatopoulos G, Pandit H, Glyn-Jones S, McLardy-Smith P, Gundle R, Whitwell D, Gill HS, Murray DW. Optimal acetabular orientation for hip resurfacing. *J Bone Joint Surg* 2010;92B:1072-8.
26. Keegan GM, Learmonth ID, Case CP. Orthopaedic metals and their potential toxicity in the arthroplasty patient. *J Bone Joint Surg* 2007;89B:567-73.
27. Jiang Y, Zhang K, Die J, Shi Z, Zhao H, Wang K. A Systematic Review of Modern Metal-on-Metal Total Hip Resurfacing vs Standard Total Hip Arthroplasty in Active Young Patients. *J Arthroplasty*. 2010 Sep 17. [Epub ahead of print]
28. Roberts P, Grigoris P. Removal of acetabular bone in resurfacing arthroplasty of the hip. *J Bone Joint Surg* 2006;88B:839.
29. Schnurr C, Michael JW, Eysel P, König DP. Imageless navigation of hip resurfacing arthroplasty increases the implant accuracy. *Int Orthop* 2009;33:365-72
30. Romanowski JR, Swank ML. Imageless navigation in hip resurfacing: avoiding component malposition during the surgeon learning curve. *J Bone Joint Surg* 2008;90A:65-70.
31. Seyler TM, Lai LP, Sprinkle DI, Ward WG, Jinnah RH. Does computer-assisted surgery improve accuracy and decrease the learning curve in hip resurfacing? A radiographic analysis. *J Bone Joint Surg* 2008;90A:71-80.
32. Amstutz HC, Campbell PA, Le Duff MJ. Fracture of the neck of the femur after surface arthroplasty of the hip. *J Bone Joint Surg* 2004;86A:1874-7.
33. Shimmin AJ, Bare J, Back DL. Complications associated with hip resurfacing arthroplasty. *Orthop Clin North Am* 2005;36:187-93.
34. Beaulé PE, Dorey FJ, LeDuff M, Gruen T, Amstutz HC. Risk factors affecting outcome of metal-on-metal surface arthroplasty of the hip. *Clin Orthop Rel Res* 2004;418:87-93.
35. Marker DR, Seyler TM, Jinnah RH, Delanois RE, Ulrich SD, Mont MA. Femoral neck fractures after metal-on-metal total hip resurfacing: a prospective cohort study. *J Arthroplasty* 2007;22:66-71.
36. Hurst JM, Millett PJ. A simple and reliable technique for placing the femoral neck guide pin in hip resurfacing arthroplasty. *J Arthroplasty* 2010;25:832-4.
37. Raaijmakers M, Gelaude F, De Smedt K, Clijmans T, Dille J, Mulier M. A custom-made guide-wire positioning device for Hip Surface Replacement Arthroplasty: description and first results. *BMC Musculoskelet Disord* 2010;11:161.
38. Davis ET, Gallie P, Macgroarty K, Waddell JP, Schemitsch E. The accuracy of image-free computer navigation in the placement of the femoral component of the Birmingham Hip Resurfacing: a cadaver study. *J Bone Joint Surg* 2007;89B:557-60.
39. Belei P, Skwara A, De La Fuente M, Schkommodau E, Fuchs S, Wirtz DC, Ka"mper C, Radermacher K. Fluoroscopic navigation system for hip surface replacement. *Comput Aided Surg* 2007;12:160-7.
40. Cobb JP, Kannan V, Brust K, Thevendran G. Navigation reduces the learning curve in resurfacing total hip arthroplasty. *Clin Orthop Relat Res* 2007;463:90-7.
41. Bailey C, Gul R, Falworth M, Zadow S, Oakeshott R. Component alignment in hip resurfacing using computer navigation. *Clin Orthop Relat Res* 2009;467:917-22.
42. Kaleta M, Ga"dzik TS, Wroński S, Gajda T, Bozek M. Revision hip arthroplasty management tactics--own experience [Article in Polish]. *Chir Narzadow Ruchu Ortop Pol* 2006;71:431-8.
43. Wierusz-Kozłowska M, Markuszewski J, Wozniak W. Osteoarthritis secondary to the developmental hip dysplasia-treatment options in young patients [Article in Polish]. *Chir Narzadow Ruchu Ortop Pol*. 2005;70:325-9.
44. Paratte S, Argenson J. Validation and usefulness of a computer-assisted cup-positioning system in total hip arthroplasty. A prospective, randomized, controlled study. *J Bone Joint Surg* 2007;89A:494-99.
45. Beckmann J, Stengel D, Tingart M, Gotz J, Grifka J, Luring C. Navigated cup implantation in hip arthroplasty: a meta-analysis. *Acta Orthop* 2009;80:538-44.
46. Gandhi R, Marchie A, Farrokhyar F, Mahomed N. Computer navigation in total hip replacement: a meta-analysis. *Int Orthop* 2009;33:593-7.
47. Reininga I, Zijlstra W, Wagenmakers R, Boerboom A, Huijbers B, Groothoff J, Bulstra S, Stevens M. Minimally invasive and computer-navigated total hip arthroplasty: a qualitative and systematic review of the literature. *BMC Musculoskelet Disord* 2010;11:92.
48. Kowalski M, Górecki A. Total knee arthroplasty using the OrthoPilot computer-assisted surgical navigation system. *Ortop Traumatol Rehabil* 2004;6:456-60.
49. Saithna A, Dekker AP. The influence of computer navigation on trainee learning in hip resurfacing arthroplasty. *Comput Aided Surg* 2009;14:117-22.

50. Langlotz F, Stucki M, Bächler R, Scheer C, Ganz R, Berlemann U, Nolte LP. The first twelve cases of computer assisted peri-acetabular osteotomy. *Comput Aided Surg* 1997;2:317-26.
51. Krüger S, Zambelli PY, Leyvraz PF, Jolles BM. Computer-assisted placement technique in hip resurfacing arthroplasty: improvement in accuracy? *Int Orthop* 2009;33:27-33.
52. Synder M, Kozłowski P, Marciniak M, Dorman T. Revision hip arthroplasty in aseptic loosening of total hip replacement. *Ortop Traumatol Rehabil* 2001;3:34-7.
53. Renkawitz T, Tingart M, Grifka J, Sendtner E, Kalteis T. Computer-assisted total hip arthroplasty: coding the next generation of navigation systems for orthopedic surgery. *Expert Rev Med Devices* 2009;6:507-14.
54. Sandri A, Regis D, Magnan B, Luminari E, Bartolozzi P. Hip resurfacing using the anterolateral Watson-Jones approach in the supine position. *Orthopedics* 2009 Jun;32:406.
55. Lin F, Lim D, Wixson RL, Milos S, Hendrix RW, Makhsous M. Limitations of imageless computer-assisted navigation for total hip arthroplasty. *J Arthroplasty*: 2 September 2010. [Epub ahead of print].

---

**Liczba słów/Word count:** 3806

**Tabele/Tables:** 0

**Ryciny/Figures:** 4

**Piśmiennictwo/References:** 55

*Adres do korespondencji / Address for correspondence*

*Mr Wasim S Khan, Clinical Lecturer, University College London Institute of Orthopaedics and Musculoskeletal Science, Royal National Orthopaedic Hospital, Stanmore, Middlesex, London, HA7 4LP, UK, Tel./fax: +44 (0) 7791 025554, e-mail: wasimkhan@doctors.org.uk*

*Otrzymano / Received 08.11.2010 r.  
Zaakceptowano / Accepted 14.03.2011 r.*