

The Treatment of Intertrochanteric Fractures of the Femur with Proximal Femoral Nail

Alessandro Geraci^{1(A,C,E)}, Umberto Martorana^{2(B,D)}

¹ Orthopaedic and Traumatology Department, Santa Maria del Prato Hospital, Feltre, Italy

² Orthopaedic and Traumatology Department, University of Palermo, Italy

SUMMARY

Background. The incidence of fractures in the trochanteric area has risen with the increasing numbers of elderly persons with osteoporosis. The imperative goals of treatment are early mobilization by means of stable fixation using as minimally invasive a procedure as possible. Nowadays, there is an increasing interest in intramedullary nailing, especially for unstable intertrochanteric fractures. The aim of the present paper is to assess the efficacy of closed intramedullary osteosynthesis with the proximal femoral nail (Endovis®) in the treatment of peritrochanteric fractures to solve the problems associated with the use of intramedullary fixation devices.

Material and methods. The authors describe their experience with 87 stable and unstable proximal extracapsular femoral fractures treated with the Endovis femoral nail from July 2007 to March 2009. The results were evaluated clinically, functionally and radiographically during the 1st, 3th, 6th and 12th months post-op. Pre-injury activity and functional levels were recorded using the modified Harris hip score and V.A.S. score.

Results. Postoperative radiographs showed a near-anatomical fracture reduction in 85% of patients. Three were the cases of cut-out, one case of valgus and two cases of shortening of the operated leg (<1 cm). The Harris Hip Score increased between the thirtieth and ninetieth postoperative day, accompanied by a significant decrease in pain symptoms and functional limitation.

Conclusions. 1. The application of an intramedullary nail provides primary stability of the fracture. 2. The Endovis nail constitutes a powerful synthesis for stable and unstable fractures of the trochanteric region, in which is difficult to reconstruct appropriate continuity between the medial and posterior cortical layers. 3. The good mechanical stability of the nail allows rapid mobilization and early functional recovery. 4. The presence of an additional anti-rotational screw and the free sliding mechanism of the lag screw may increase rotational stability of cervico-cephalic fragments and decrease overload on the femoral head.

Key words: hip fracture, endomedullary nail, inter-trochanteric fracture, fracture fixation, bone nails.

BACKGROUND

Intertrochanteric fractures constitute one of the commonest fractures of the hip. The incidence of fractures in the trochanteric area has risen with the increasing numbers of elderly persons with osteoporosis [1,2]. Although a large number of different implants are available for fixation, the ideal implant for the treatment of intertrochanteric fractures is still a matter for discussion. The imperative goals of treatment are early mobilization by means of stable fixation using as minimally invasive a procedure as possible. Nowadays, there is an increasing interest in intramedullary nailing, especially for unstable intertrochanteric fractures [3,4,5]. Several clinical and biomechanical studies have analysed the results of different implants such as the dynamic hip screw (DHS), the Gamma nail (GN) and the proximal femoral nail (PFN). Those devices have suffered cut-out, implant breakage, femoral shaft fractures and subsequent loss of reduction in the clinical setting [6,7,8]. However, preoperative and postoperative technical complications are common in some cases, necessitating a new surgical treatment. The Endovis® proximal femoral nail (EN) has been designed by Citieffe® (Italy) to solve the problems associated with the use of intramedullary fixation devices. Some studies have demonstrated a good outcome with few complications after treatment with this intramedullary femoral nail [9,10]. EN is made of a titanium alloy with a cervicodiaphyseal angle of 130 degrees, a metaphyseal angle of 5 degrees and a total length of 195 mm (standard nail) or 220 mm (medium nail). The diameter is 13 mm (standard nail) or 13.5 mm

(medium nail) proximally and 10 mm distally. There are two holes for cephalic screw insertion and one for the distal screw. The cephalic screws are available in nine length sizes, 7.5 mm diameter, self-drilling and self-taping. The distal screw is available in four sizes, 5 mm diameter, self-drilling and self-taping. The distal tip of the nail has a diapason section (Tab. 1).

MATERIALS AND METHODS

EN was performed in 87 patients with proximal extra-capsular femoral fractures at the Department of Orthopaedic Surgery of the University of Palermo between July 2007 and March 2009 (Tab. 2). There were 69 (79.3%) females and 18 (20.7%) males in the group, with a mean age of 72.3 years (range: 56-91). In accordance with the recommendations of the AO/ASIF (Fig. 1), the preoperative radiographs were classified as 31-A1 (stable pertrochanteric) in 33 patients, 31-A2 (unstable pertrochanteric) in 37, and 31-A3 (unstable intertrochanteric) in 17 (Fig. 2). During surgery, all fractures were treated by closed reduction under C-arm fluoroscopy guidance. Spinal anaesthesia was used in all patients. All operations were performed by the same group of experienced surgeons. The intramedullary femoral nail used was the EN in its standard or medium design (Fig. 3). The surgical technique followed the manufacturer's instructions. The intramedullary nail was interlocked proximally with two screws (cephalic and anti-rotational) and distally with one or 2 screws. The operative time, blood loss during surgery, fluoroscopy time, and the amount of blood transfused were recorded. After a closed reduction of the fracture, a long-

Tab. 1. Characteristics of standard and medium Endovis nail

	Standard Endovis Nail	Medium Endovis Nail
Material	Titanium	Titanium
Cervicodiaphyseal angle	130°	130°
Metaphyseal angle	5°	5°
Total length	195 mm	220 mm
Diameter proximally	13 mm	13.5 mm

Tab. 2. Epidemiology of the study group

ENDOVIS NAIL (N=87)	
Male	18 (20,7%)
Female	69 (79,3%)
Age	56 to 91 years (mean, 72,3)
Type of fracture: 31 A 1	33 (38%)
Type of fracture: 31 A 2	37 (42,5%)
Type of fracture: 31 A 3	17 (19,5%)
Post-operative blood transfusions	31 (35,6%)
Hospital stay	5 to 11 days (mean, 7)

itudinal incision started proximal to the greater trochanter apex and extended proximally about 4-10 cm, depending on the size or obesity of the patient. After splitting the aponeurosis, the entry point was made just on the tip of the greater trochanter. The nail was inserted into the femoral diaphysis without reaming. Our goal was to insert the hip screw under the mid-line of the femoral neck, advancing the tip of the screw close to the subarticular surface of the femoral head. Tip to Apex Distance (TAD) was measured from the tip of the guide wire. When TAD was less than 25 mm, we proceeded to reaming and insertion of the cephalic screw. Fluoroscopic screening was performed to ensure that the joint line was not penetrated after screw placement. Distal locking was made preferably with 2 screws. In all cases antithrombotic prophylaxis was given using low molecular weight heparin (Fraxiparine), and antibiotic prophylaxis was provided (Cefazolin). The rehabilitation protocol was identical, and the patients were mobilised on the first postoperative day. Patients were allowed to mobilise on postoperative day 2, and weight-bearing walking was initiated on day 3 or 4 as tolerated. The average follow-up period was 12 months (range 9-18 months). Clinical and radiographic examinations were performed at the time of admission and at three, six and 12 months postoperatively. We noted any change in the position of the implants and the progress of fracture union. A minimum follow-up of 3 months was required. The average follow-up period was 6.5 months (range, 4 to 21 months). Pre-injury activity and functional levels were recorded using the modified Harris hip score and VAS score.

RESULTS

The mean time needed for the two intramedullary Endovis nails procedures was 24.4 minutes (range, 18-47). In 90% of the patients, the fracture was the

result of a domestic fall; in the remaining 10%, it had been caused by a vehicular accident. Perioperative fluoroscopy screening lasted a mean of 137 seconds (104-159 seconds). In AP radiographs, 100% of the lag screws appeared to be placed in the inferior part of the femoral head. In lateral radiographs, 90% of the lag screws appeared to be placed centrally, 8% anteriorly, and 2% posteriorly. Mean blood loss was 120 ml (80-200). Three patients required blood transfusion with a mean volume of 1.5 units. Mean hospital stay was 7 days (5-11 days). Postoperative radiographs showed a near-anatomical fracture reduction in 85% of the patients (Fig. 4). According to the Garden alignment index, 71 cases were classified as very good, nine cases as good and seven as satisfactory. Implant positioning with an average TAD of 18.9 mm (range 9-30 mm) was acceptable. The patients were followed up at 3, 6 and 12 months. There were no cases of deep infection and no failures or breakages due to implant fatigue. Fracture of the greater trochanter during insertion of the nail was seen in one patient, who was treated conservatively. Six patients (6.8%) died in the first year and two patients (2.3%) were lost to follow up after 6 months. Repeat surgery was necessary in five patients (5.7%). Four cases of cut-out (Fig. 5) were noted. They were associated with malposition of the proximal lag screws and were treated using a new intramedullary Endovis nail. One patient had a traumatic fracture of the femoral shaft below the tip of the implant. This case was treated using an Endovis long nail (340 mm). Moreover, one case of valgus was revealed. Three patients demonstrated medial displacement of the femoral diaphysis with consequent shortening of the affected femur. All fractures were considered clinically healed within three months in all patients, with the exception of those with mechanical failure, who needed reoperation. Active and passive exercises

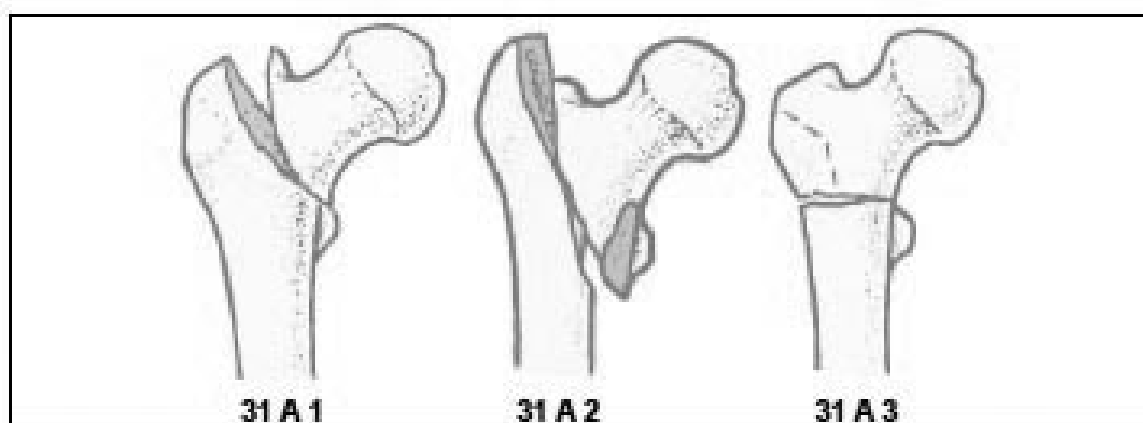


Fig. 1. AO Classification System of Proximal lateral femoral fractures

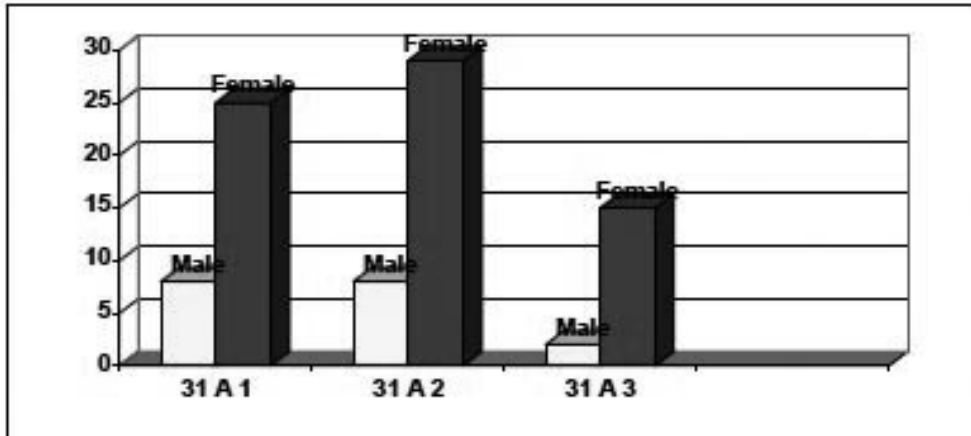


Fig. 2. Type and distribution of proximal extra-capsular femoral fracture in the study

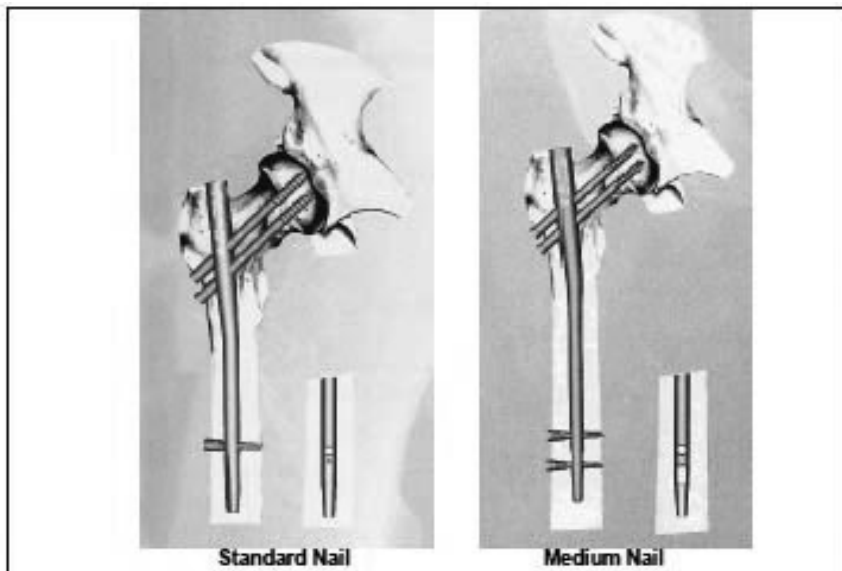


Fig. 3. Standard and medium Endovis nail

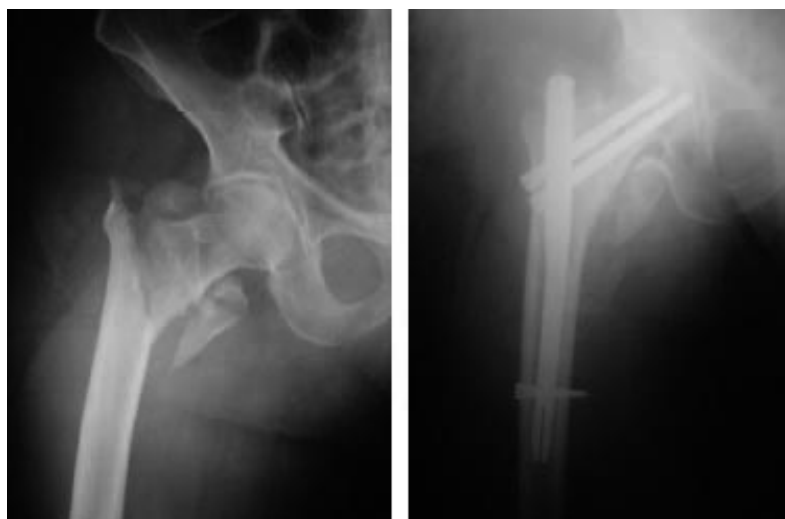

Fig. 4. Pertrochanteric fracture type 31A2 treated with Endovis medium nail

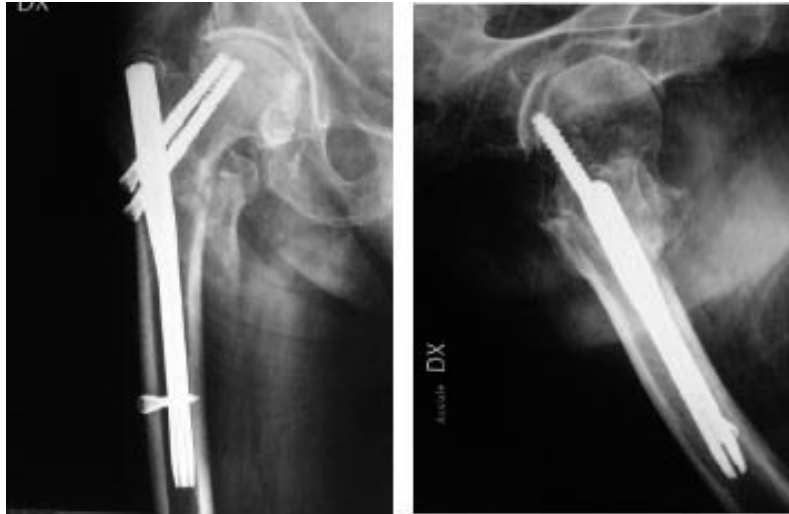

Fig. 5. A case of cut-out

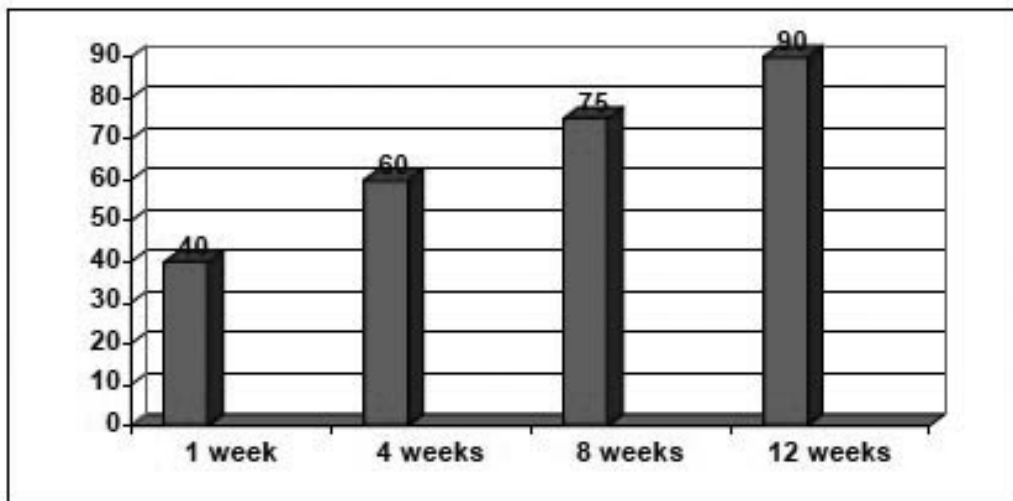


Fig. 6. Result of analysis of Harris Hip Score

were initiated within 48 h of surgical treatment. The VAS scale on the second day had an average of 9 (range 7-10), compared to 7 (range 5-9) on day 30, 6 (range 5-7) on day 90, and 4 (range 1-6) on day 90. The Harris Hip Score increased between the thirtieth and ninetieth postoperative day from an average of 60 to 85, accompanied by a significant decrease in pain symptoms and functional limitation (Fig. 6).

DISCUSSION

Trochanteric fractures occur mostly in elderly patients, and the outcome may be extremely poor if there is prolonged bedrest.

An osteoporosis-related decrease [11] in the mechanical properties of bone leads to frequent fractures following low-energy injuries, usually a fall at ground level. Peritrochanteric fractures of the femur occur much less frequently in younger persons and

are mostly due to high-energy injuries such as traffic accidents or falls from a height.

Surgery is the mainstay of treatment for both displaced and non-displaced intertrochanteric fractures. The primary reason for surgery is to allow early mobilization of the patient, with partial weight-bearing restrictions depending on the stability of the reduction [12]. The ideal implant for stabilization of peritrochanteric fractures is still under debate. Many internal fixation devices have been recommended for the treatment of peritrochanteric fractures, including extramedullary and intramedullary implants [13,14]. The dynamic hip screw (DHS), initially introduced by Clawson in 1964, remains the implant of choice because of its favourable results and low rate of non-union and failure [15,16]. This implant consists of a large lag screw placed in the centre of the femoral neck and head and a side plate along the lateral femur

[17]. The screw-plate interface angle is variable and depends on the anatomy of the patient and the fracture. The advantage of the sliding lag screw, compared with the static screw, is that it allows for impaction of the fragments; this impaction increases the bone-on-bone contact, promoting osseous healing while decreasing implant stress; the disadvantage is shortening and rotation at the fracture site, both of which are commonly encountered [18]. Although repair of an intertrochanteric fracture is often referred to as open reduction with internal fixation (ORIF), the term closed reduction with internal fixation (CRIF) may be more accurate. However, intramedullary nails have been gaining popularity for both stable and unstable fractures, due to certain theoretical advantages and technical ease; additionally, the small incisions result in less intraoperative blood loss. A variety of intramedullary devices have been used with different design characteristics. The main principle of this type of fixation is based on a sliding screw in the femoral neck-head fragment, attached to an intramedullary nail. The GN has been available since 1988 and was designed specifically for the treatment of these fractures in order to combine the advantages of semiclosed intramedullary nailing, a dynamic femoral neck screw and early post-operative weight-bearing. High incidence (6-17%) of femoral shaft fractures after Gamma nailing was observed in earlier studies (19, 20). It was believed that this was due to design specifics of the first generation Standard Gamma Nail, such as the length, the valgus curvature and the distal diameter. It has also been suggested that there is a disparity between the design of the nail and the geometry of the bone resulting in increased stiffness of the bone-implant system [21]. Inappropriate placement of the distal locking screws and/or misdrilling could also be responsible for some of these complications. The PFNA system was developed by the AO/ASIF in 2004. The main design characteristic of the implant is the use of a single blade with a large surface area. Insertion of the blade compacts the cancellous bone. Biomechanical tests have demonstrated that the blade has a significantly higher cut-out resistance than commonly used screw systems [22].

However, the adequacy and stability of fixation plays an important role, determining the success of surgical treatment of pertrochanteric fractures [23]. The EN is fixed with 2 screws; the larger (lag) screw is designed to carry most of the load, and the smaller screw (the hip pin) is to provide rotational stability. If the hip pin is longer than the lag screw, vertical forces would increase on the hip pin and start to induce cut-out, a knife effect or Z-effect. The right

position of the lag screw near the centre of the femoral head and neck, in both anteroposterior and lateral views, is critical and has been emphasized by many authors. Baumgartner et al. [24] indicated the significance of tip-apex distance value in the placement of the proximal lag screw and Den Hartog [25] showed that this optimal position prevents the rotation of the femoral head and neck during lag screw insertion. The lag screw should be inserted into the femoral head as deeply as noted in the AP view, and centrally in the lateral view. The tip of the lag screw should always be inferior to the centre of the femoral head. Anatomic and biomechanical studies have shown that the superomedial quadrant of the femoral head is the weakest part for the implant, and therefore proper positioning of the screw is emphasised. Cut-out is usually the result of poor positioning of the proximal screw in the femoral head, particularly in osteoporotic bone. The cut-out rate with a PFN-A is reportedly 0.6 to 8% [26, 27]. The complication of cut out was often reported in the literature when trochanteric fractures were treated with gamma nail [28,29]. Makridis et al. [30] studied cut-out in 64 patients. Three cases of cut-out, associated with malposition of the proximal lag screws, occurred with the ENDOVIS nail. In a study of Veronail, another nail, Lavini et al. [31] observed screw cut-out in 4.5% of cases. In our study, the lag screw was inserted close to the subchondral bone, and the hip pin superior to the femoral head. We used two lag screws in our EN design in order to enhance stability and to decrease the incidence of lag screw cut-outs. In our study cut-out was observed in 4 patients (4.7%). Anatomical fracture reduction and the insertion of the inferior lag screw as close as possible to the inferior cortex of the femoral neck is strongly recommended because the compression trabeculae and tensile trabeculae of the proximal femur intersect at the inferior part of the femoral neck, constituting the strongest architecture. However, our study revealed that the Endovis blade cut-out can be due to inadequate insertion. Careful and adequate insertion of the blade or lag screw may be a more important consideration than biomechanical stability. In this study, operating time and operative blood loss seemed to be identical compared with a previous study of the other intramedullary femoral nail. The Endovis femoral nail was developed to solve such problems as the perioperative and postoperative technical complications described in patients treated with the gamma nail. According to the literature, these complications, which necessitate reoperation, occur in 3% to 7% of cases. The ambulatory status after an operation for an intertrochanteric fracture depends on a number of factors. Specific parameters

such as the patients' preoperative walking capability, their medical condition and comorbidities were similar in both groups. The overall walking competence in patients treated with the Endovis was very high. An improvement to 44% of the pre-operative modified Harris score was achieved during the hospitalisation period; this increased to 83% after 4 months. This compares very favourably with other published studies; in the largest single series of patients treated with the DHS this was 35.1%.

CONCLUSIONS

1. The application of an intramedullary nail (EN) provides primary stability of the fracture, whose synthesis is then completed from the cervico-cephalic screws and possibly from the distal locking screws.

2. The EN constitutes a powerful synthesis for stable and unstable fractures of the trochanteric region in which it is difficult to reconstruct appropriate continuity between the medial and posterior cortical layers.
3. The good mechanical stability of the nail allows rapid mobilization and early functional recovery and provides a self-sufficient solution for older persons who need a quick and good recovery for physical and psychological reasons.
4. The presence of an additional anti-rotational screw and the free sliding mechanism of the lag screw may increase rotational stability of cervico-cephalic fragments and decrease overload on the femoral head.

REFERENCES

1. Gulberg B, Duppe H, Nilsson B (1993) Incidence of Hip Fractures in Malmo, Sweden (1950–1991). *Bone* 14[Suppl 1]:23–29.
2. Kannus P, Oarkkari J, Sievanen H. Epidemiology of hip fractures. *Bone* 1996;18[Suppl]:57–63.
3. Baumgaertner Mr, Curtin SL. intramedullary versus extramedullary fixation for the treatment of intertrochanteric hip fractures. *Clin Orthop Rel Res.* 1998;348:87-94.
4. Adams CI, Robinson CM, Court-Brown CM, McQueen MM. Prospective randomized controlled trial of an intramedullary nail versus dynamic hip screw and plate for intertrochanteric fractures of the femur. *J Orthop Trauma* 2001; 15:394–400.
5. Klinger HM, Baumus MH, Eckert M, Neugebauer R. A comparative study of unstable per- and intertrochanteric femoral fractures treated with dynamic hip screw (DHS) and trochanteric buttress plate vs. proximal femoral nail (PFN). *Zentralbl Chir* 2005; 130(4):301-306.
6. Beatrix H, Andre G. Complications following the treatment of trochanteric fractures with the gamma nail. *Arch Orthop Trauma Surg.* 2004;124:692–698.
7. Domingo L, Cecilia D, Herrera A, et al. Trochanteric fractures treated with a proximal femoral nail. *Int Orthop.* 2001;25: 298–301.
8. Papasimos S, Koutsojannis CM, Panagopoulos A. A randomised comparison of AMBI, TGN and PFN for treatment of unstable trochanteric fractures. *Arch Orthop Trauma Surg.* 2005;125:462–468
9. Caraffa V., De Vita D., La forgia R., Sessa G., Varsalona R., Girolami M., Dallari D., Magnani G. Treatment of peritrochanteric fractures with the Endovis BA cephalomedullary nail: multicenter study of 1091 patients. *J Orthopaed Traumatol* 2007; 8:111-116.
10. Efstathopoulos Enicolas, Nikolaou SVassilios, Lazaretos TJohn: Intramedullary fixation of intertrochanteric hip fractures: a comparison of two implant designs. *Int Orthop* 2007, 31:71-76.
11. Bączyk G.: Quality of Life of Women with Osteoporosis – Review of Literature, *Ortopedia Traumatologia Rehabilitacja*, 2009, 11, 291-303
12. Koval KJ, Zuckerman JD. Hip fractures: II. Evaluation and treatment of intertrochanteric fractures. *J Am Acad Orthop Surg* 1994;2:150–6.
13. Lorich DG, Geller DS, Nielson JH. Osteoporotic pertrochanteric hip fractures: management and current controversies. *Instr. Course Lect.* 2004; 53: 441-454.
14. Domingo LJ, Cecilia D, Herrera A, Resines C. Trochanteric fractures treated with a proximal femoral nail. *Int Orthop.* 2001;25:298-301.
15. Parker MJ, Handoll H: Gamma and other cephalocondylic intramedullary nails versus extramedullary implants for extracapsular hip fractures in adults. *Cochrane Database Syst Revi* 2005.
16. Wolfgang GL, Bryant MH, O'Neill JP: Treatment of intertrochanteric fracture of the femur using sliding screw plate fixation. *Clin Orthop* 1982, 163:148-58.
17. Kim WY, Han C-H, Park J-I, Kim JY. Failure of intertrochanteric fracture fixation with a dynamic hip screw in relation to preoperative fracture stability and osteoporosis. *Int Orthop* 2001;25(6):360–362.
18. Pajarinen J, Lindahl J, Michelsson O, Savolainen V, Hirvensalo E. Pertrochanteric femoral fractures treated with a dynamic hip screw or a proximal femoral nail. *J Bone Jt Surg (Br)*, 1992;74-B:352–357.
19. Butt MS, Krikler SJ, Nafie S, Ali MS: Comparison of dynamic hip screw and gamma nail: a prospective, randomized, controlled trial. *Injury* 1995, 26(9):615-618.
20. Bojan AJ, Beimel C, Speitling A, Taglang G, Ekholm C, Jonsson A. 3066 consecutive Gamma Nails. 12 years experience at a single centre. *BMC Musculoskelet Disord.* 2010;26:11:133.

21. Radford PJ, Needoff M, Webb JK: A prospective randomised comparison of the dynamic hip screw and the gamma locking nail. *J Bone Joint Surg Br* 1993, 75(5):789-793.
22. Sommers MB, Roth C, Hall H, et al. A laboratory model to evaluate cutout resistance of implants for peritrochanteric fracture fixation. *J Orthop Trauma*. 2004;18:361-8.
23. Egol KA, Kubiak EN, Fulkerson E, Kummer FJ, Koval KJ. Biomechanics of locked plates and screws. *J Orthop Trauma* 2004;18:488-93.
24. Baumgaertner MR, Curtin SL, Lindskog DM, Keggi JM: The value of the tip-apex distance in predicting failure of fixation of peritrochanteric fractures of the hip. *J Bone Joint Surg Am* 1995, 77:1058-1064.
25. Den Hartog BD, Bartal E, Cooke F: Treatment of the unstable intertrochanteric fracture. Effect of the placement of the screw, its angle of insertion, and osteotomy. *J Bone Joint Surg Am* 1991, 73(5):726-33.
26. Al-yassari G, Langstaff RJ, Jones JM, Al-Lami M. The AO/ASIF proximal femoral nail (PFN) for the treatment of unstable trochanteric femoral fracture. *Injury* 2002;33:395-9
27. Simmermacher RK, Bosch AM, Van der Werken C. The AO/ASIF-proximal femoral nail (PFN): a new device for the treatment of unstable proximal femoral fractures. *Injury* 1999;30:327-32.
28. Smith JT, Goodman SB, Tischenko G. Treatment of comminuted femoral subtrochanteric fractures using the Russell-Taylor reconstruction intramedullary nail. *Orthopedics* 1991;14:125-9.
29. Barquet A, Mayora G, Fregeiro J, Lopez L, Riemzi D, Francescoli L. The treatment of subtrochanteric nonunions with the long gamma nail: twenty-six patients with a minimum 2-year follow-up. *J Orthop Trauma* 2004;18:346-53.)
30. Makridis KG, Georgaklis V, Georgoussis M, Mandalos V, Kontogeorgakos V, Badras L. Comparing two intramedullary devices for treating trochanteric fractures: A prospective study. *J Orthop Surg Res*. 2010 Feb 18;5:9.
31. Lavini F, Renzi-Brivio L, Ausilia R, Cherubino F, Di Seglio PL, Galante N, Leonardi W, Manca M. The treatment of stable and unstable proximal femoral fractures with a new trochanteric nail: results of a multicentre study with the Veronail. *Strategies Trauma Limb Reconstr*. 2008;3(1):15-22.

Liczba słów/Word count: 3742

Tabele/Tables: 2

Ryciny/Figures: 6

Piśmiennictwo/References: 31

Adres do korespondencji / Address for correspondence

Dr. Alessandro Geraci

Via Montegrappa 18/C Feltre, Italy

Phone: +393284527728, e-mail: geracialessandro@libero.it

Otrzymano / Received

31.07.2011 r.

Zaakceptowano / Accepted

03.10.2011 r.