

Inverted Cup Prosthesis to Treat Recurrent Hip Dislocation in Frail Elderly Patients

Ramzi Harake^(A,B,E,F), Sascha Colen^(E,F), Michiel Mulier^(A,B,E,F)

Department of Orthopedic Reconstructive Hip Surgery, UZ Pellenberg, Katholieke Universiteit Leuven, Belgium

SUMMARY

Recurrent hip dislocation has become an increasing problem in patients who had multiple component revision in total hip arthroplasty. These are often frail elderly patients with loss of constraining soft tissue envelope around the hip and an excessive weakness of the abductor mechanism. We present a simple technique for open reduction of a dislocated hip using a custom-made fully constrained construct with potential for preserving the well fixed femoral implant and parts of the acetabular component. The custom-made constrained construct consists of the application of an inverted cup over the femoral neck or head, the cup being fixed to the acetabular insert with screws.

Three frail elderly patients have been successfully treated. One specific case is described in detail.

In frail elderly patients who may have undergone several revision surgeries, it is important to preserve components of the total hip replacement when possible. The proposed technique may be an alternative solution for these patients.

BACKGROUND

Hip dislocation is one of the most frequently occurring complications of total hip replacement (THR). The Nordic registry reports that in Denmark, 34% of the revisions were due to dislocation, as compared to 23% in Sweden and Norway [1]. The risk of dislocation increases with the number of hip surgeries, which may, in turn, be responsible for gluteal deficiency, soft tissue imbalance, component malposition, impingement, and neuromuscular disorders.

Revision surgery should aim to achieve stability of the joint implants and restore the normal hip biomechanics, while preserving bone stock [2,3]. In frail elderly patients, with recurrent dislocation a technique that allows the preservation of the components of the prosthesis is needed.

We present a simple technique for open reduction of a dislocated hip using a custom-made fully constrained construct with potential for preserving the femoral implant and parts of the acetabular construct.

PATIENT SELECTION

An 82-year-old female received a primary total hip prosthesis (THP) for arthritis of the left hip 50 years ago. Three years ago she had a stem revision with trochanter cerclage for a periprosthetic femoral fracture. One year later she had an acetabular component revision with an acetabular reconstruction cage and a cemented polyethylene insert for aseptic loosening. One year later a large porous-coated revision cup was used together with an allograft to fill

the posterior and superior wall defect. Because of recurrent dislocations the polyethylene acetabular insert was replaced with a constrained insert. Ten months later a new revision of the acetabular component was performed with the use of allograft for structural support of the superior bone loss and a Kerboul cross with a cemented constrained liner. Due to the extreme laxity and loss of soft tissue, the hip prosthesis dislocated again and the cemented constrained cup was pulled out.

Because of the multiple revisions and loss of capsular and muscular restraints a custom made full constrained construct was used (Fig. 1).

TECHNICAL DESCRIPTION

If the polyethylene cup is still well fixed, it can be left in place. In our case, the polyethylene liner was pulled out and needed to be replaced. The Kerboul cross was still well fixed and was therefore left in place. The superior wall defect was filled with a freeze-dried bone graft and a titanium mesh. First a flanged polyethylene cup (diameter 43 mm) was fixed with 80 g cement into the Kerboul cross in a 10° anteversion position.

In the described patient, the head (diameter 28 mm) of the femoral component could not be removed from the neck. Because further attempts might have damaged the neck and the stem, the head was left in place.

A new polyethylene insert with a size that matches the acetabular insert, was prepared to fit over the

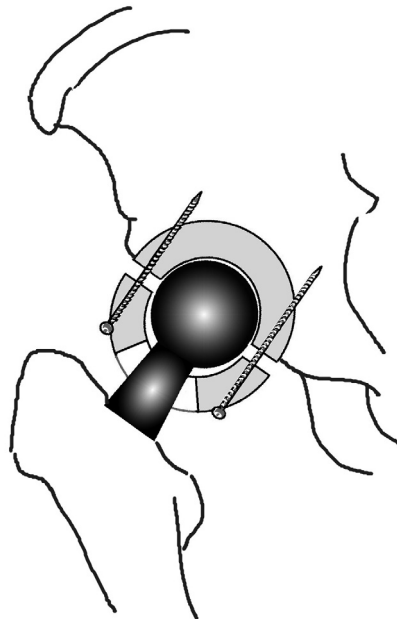


Fig. 1. Schematic drawing of the fixation of the inverted cup

head of the femoral stem. When the head cannot be removed, as in this case, an opening 1 mm smaller than the size of the head is made with a high speed burr in the apex of the 44 mm diameter insert (Fig. 2a). During drilling, flushing is used to limit and wash off the particles. A trial head component is used to assess and adjust the size of the hole.

If the head can be removed from the stem, the burr hole will be made a few millimetres larger than the diameter of the neck.

The border surface of the inverted cup should be matched with the border surface of the cemented cup. If necessary, the surface border of the inverted cup can be adjusted with a forceps or a saw to fit perfectly over the border of the cemented cup.

The new insert with the burr hole is then inverted, with the apex first pushed over the femoral head or neck. A regular compression device can be used when this is manually not possible (Figure 2b)

Once the inverted cup is squeezed over the head of the femoral component, the hip is reduced and the border surface of the inverted cup fits the border of the cemented cup. The inverted cup is fixed on the cemented cup in sequence of drill and screw fixation (Fig. 3). A drill diameter of 2.5 millimetre and screws of 3.2 millimetre diameter were used.

The border surface of the inverted cup should be placed and fixed in a neutral position over the border of the cemented cup. The centre axis can be adjusted to allow full extension of the hip with limited flexion. Anteversion of the inverted cup should be avoided to allow comfortable extension of the hip in a relaxed supine position without posterior impingement of the neck on the inverted cup. Also using a larger diameter of the inverted polyethylene liner gives more border width for positioning and placing screws without damaging the head of the femoral component.

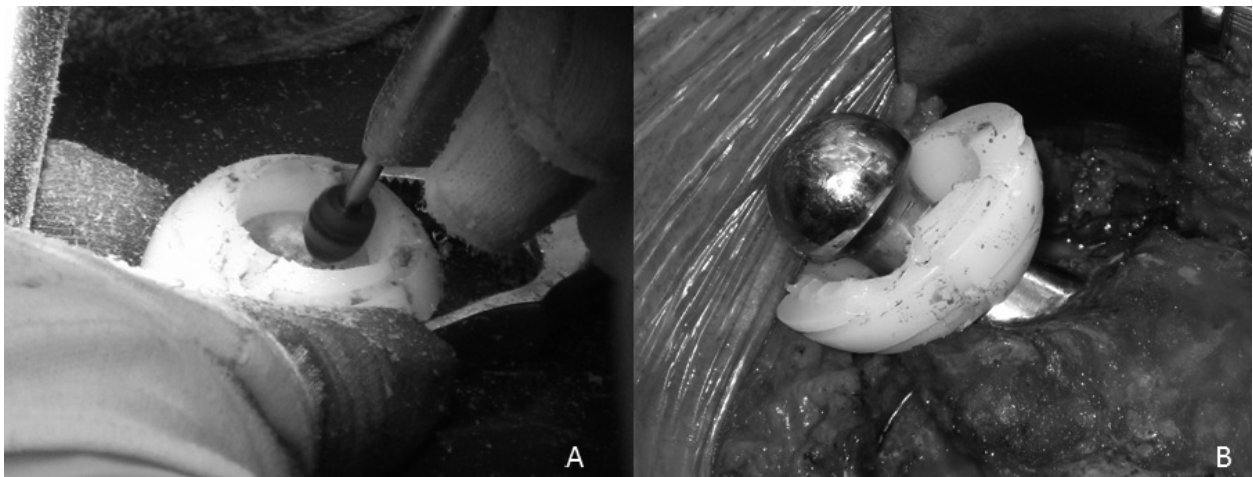


Fig. 2. a. A hole is made in the apex of the cup using a high speed drill burr, adjusting the hole until the trial head fits snugly. b. The inverted cup is squeezed over the femoral prosthesis head

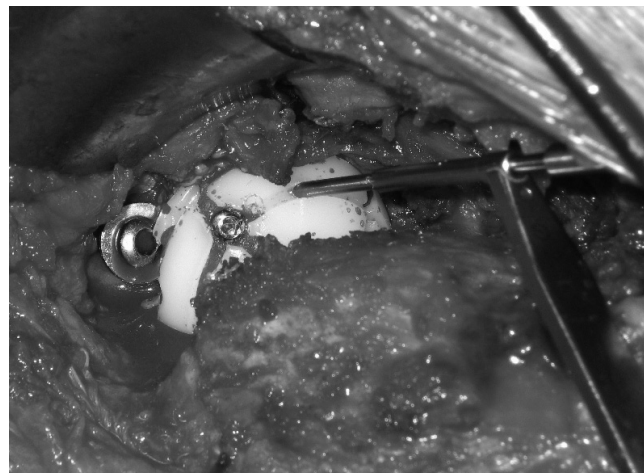

Fig. 3. Fixing the inverted cup onto the cemented cup with screws at the border of both cups

After fixation of the inverted cup, the range of motion should be tested .

OUTCOME

The 82-year-old patient had a hip mobility of 40° flexion and 25° abduction before impingement of the neck on the edge of the opening of the inverted cup was obtained. The hip showed slight posterior impingement in the neutral position.

Postoperative radiographs demonstrated an acceptable position of the acetabular construct. In a supine position in bed, a slight flexion of the hip of ten degrees was the most comfortable position for the patient. After two weeks the patient started walking limited distances with full bearing with external support. At six months after the surgery, she is able to walk relatively pain-free inside her house with external support, and no dislocation has reoccurred.

DISCUSSION

Besides the patient described above two other patients were treated in a similar way for persistent recurrent dislocation due to the loss of a constraining soft tissue envelope and excessive weakness of the abductor mechanism as a result of multiple component revisions. In all three patients, satisfactory stability, pain control and a fair clinical outcome were achieved.

In frail elderly patients, it is important to leave well-fixed components in place. The custom-made inverted cup liner provides a satisfactory stability and clinical outcome. Because of the limited mobility of the hip and the impingement , this technique could only be used for low-demanding patients.

REFERENCES

1. Havelin LI, Fenstad AM, Salomonsson R, Mehnert F, Furnes O, Overgaard S, Pedersen AB, Herberts P, Karrholm J, Garellick G. The Nordic Arthroplasty Register Association: a unique collaboration between 3 national hip arthroplasty registries with 280,201 THRs. *Acta Orthop* 2009;80, 4: 393-401
2. Issack PS, Nousiainen M, Beksac B, Helfet DL, Sculco TP, Buly RL. Acetabular component revision in total hip arthroplasty. Part II: management of major bone loss and pelvic discontinuity. *Am J Orthop (Belle Mead NJ)* 2009;38, 11: 550-556
3. Issack PS, Nousiainen M, Beksac B, Helfet DL, Sculco TP, Buly RL. Acetabular component revision in total hip arthroplasty. Part I: cementless shells. *Am J Orthop (Belle Mead NJ)* 2009;38, 10: 509-514

The discomfort experienced by the patient during bed rest is attributed to the ten degrees' anteversion of the cemented flanged liner. A more neutral position of the liner can prevent this, allowing the patient to lie flat on the bed. The use of a larger diameter of the inverted polyethylene insert gives more space for drilling and placing screws without damaging the head.

The use of an inverted liner to obtain a full restraining cup construction in frail patients allows maintaining those parts of the prostheses that are well fixed. Therefore operation time and blood loss is considerably reduced. When the size of the head is known, the hole can be drilled into the liner before induction of anesthesia, which will again reduce operation time.

The principle of the technique using an inverted cup is similar to the constrained cup approach. Theoretically the metal head should be fixed onto the stem cone, as rigidly as possible. In our centre the metal head was applied after being heated in a rapid sterilization device. The shrinking effect of the head on the cone assures a rigid fixation.

All the patients treated with an inverted cup preserved a certain degree of motion. They could walk again, some with a walking aid, which they consider a progress compared to the situation of the recurrent dislocating hip.

SUMMARY

The ease of producing a totally constraining cup construct may be an alternative for frail elderly patients who have experienced recurrent dislocations.

Liczba słów/Word count: 1637

Tabele/Tables: 0

Ryciny/Figures: 3

Piśmiennictwo/References: 3

Adres do korespondencji / Address for correspondence

Prof. Michel Mulier

UZ Pellenberg, Dept of orthopedic surgery, Weligerveld, 1, 1312 Lubbeek

Phone: + 32 16 33 88 27, Fax: + 32 16 33 88 24, e-mail: michiel.mulier@uzleuven.be

Otrzymano / Received

09.01.2012 r.

Zaakceptowano / Accepted

18.04.2012 r.