

# Bilateral Calcaneal Stress Fractures. Case Report

**Ahmet Imerci<sup>1,2(A,F,G)</sup>, Mustafa İncesu<sup>2(A,B,E)</sup>, Muhammet Bozoglan<sup>3(C,D,F,G)</sup>,  
Umut Canbek<sup>4(A,B,D)</sup>, Hüseyin Tamer Ursavas<sup>2(B,C,E,G)</sup>**

<sup>1</sup> Department of Orthopaedics and Traumatology, Erzurum Palandoken State Hospital, Erzurum, Turkey

<sup>2</sup> Department of Orthopaedics and Traumatology, Tepecik Education and Research Hospital, Izmir, Turkey

<sup>3</sup> Department of Orthopaedics and Traumatology, Mardin Derik State Hospital, Mardin, Turkey

<sup>4</sup> Department of Orthopaedics and Traumatology, Mugla University, Mugla, Turkey

## SUMMARY

The majority of plantar heel pain is diagnosed as plantar fasciitis or heel spur syndrome. When history or physical findings are unusual or when routine treatment proves ineffective, one should consider an atypical cause of heel pain. Stress fractures of the calcaneus are a frequently unrecognized source of heel pain. In a normal population, the possibility of calcaneal stress fractures must be borne in mind with patients who have bilateral heel pain. When a stress fracture is considered, clinicians have different imaging options. First of all, x-rays must be used to evaluate for any visible osseous pathology. If plain films are inconclusive, the clinician can proceed with a bone scan or Magnetic Resonance Imaging. In the literature, calcaneal stress fractures are mostly reported in soldiers or athletes, but our case is one of a 44-year-old housewife with bilateral heel pain treated as Achilles tendinitis and plantar fasciitis for a long time. Her final diagnosis was bilateral calcaneal fracture by Magnetic Resonance Imaging.

**Key words:** bilateral heel pain; calcaneal stress fracture; treatment

## BACKGROUND

Stress fractures were first identified by Breithaupt, a Prussian army physician, in 1855 [1,2]. There are two types of stress fractures: fatigue fractures and insufficiency fractures. Calcaneal stress injuries are considered to be fairly common, especially in military recruits [3,4]. In addition, calcaneal stress fractures are more likely to occur in athletes who participate in sports that require running and jumping [5].

Heel pain is a common condition in adults that may cause significant discomfort and disability. A variety of soft tissue, osseous, and systemic disorders can cause heel pain. Narrowing the differential diagnosis begins with a history and physical examination of the lower extremity to pinpoint the anatomic origin of the heel pain. The most common cause of bilateral heel pain in adults is plantar fasciitis [5,6].

Stress fractures are frequent in the tibia, femur and metatarsal bones, but rarely reported for the calcaneal bone [7]. Because a radiograph does not always confirm a conclusive diagnosis, computed tomography or scintigraphy of the osseous structure may be necessary [8,9]. Magnetic Resonance Imaging (MRI) has proven to be an excellent method for diagnosing stress fractures and the literature contains numerous studies supporting this premise [1,10,11].

## CASE REPORT

A 44-years old woman who had a sedentary life style was seen in our outpatient clinic because of bilateral heel pain. Her history revealed that her pain had begun 3 months before and she had had non-steroidal anti-inflammatory agents because of Achilles and plantar faciitis in different hospitals. Her pain in-

creased with activity and decreased with rest. There was no association with any history of trauma or co-existing diseases. She also have a negative history of alcohol, drug and cigarette use. Her body mass index was 22.6 kg/m<sup>2</sup>. Physical examination is typically performed by squeezing the posterior third of the calcaneus between the thumb and index finger. The eythrocyte sedimentation rate, routine hematologic and biochemical analysis as well as the rheumatological tests were in the normal ranges,. Her bone mineral density (BMD) was measured from the femoral neck, proximal femur and lumbar spine (L1-L4 vertebrae) by dual-emission X-ray absorptiometry (DEXA). The T score was -1.4 standard deviations (SD). Right standard lateral x-rays were obtained and demonstrated a subtle sclerotic line in the posterior calcaneus (Fig. 1). Left standard lateral radiographs (Fig. 2) were obtained, but were unremarkable. Bilateral calcaneal MR images demonstrated a well-defined fracture line along with significant marrow edema on both T1 and T2 images (Fig. 3,4,5,6).

Her treatment was bilateral short leg splints for 2 weeks. After the casts were removed, she was allowed weight bearing with crutches, A 0.5-inch sponge rubber was inserted in her shoes. In the sixth week when the symptoms began to decline, crutches were dropped. In the eight week, the patient resumed her daily activity without any symptoms.

## DISCUSSION

A stress fracture is, by definition, a breach of the mechanical integrity of a bone as a result of the application of abnormal and repetitive stress [11]. Diagnosing calcaneal stress fractures can be a complica-

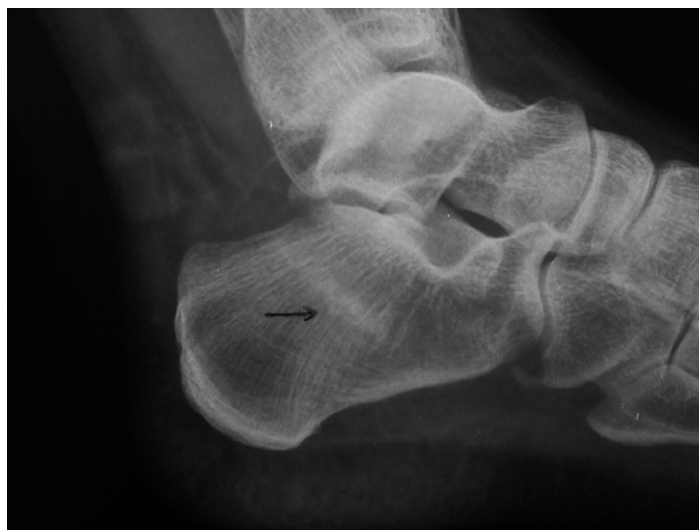

Fig. 1. A right lateral radiograph showing a subtle sclerotic line oriented from posterosuperior to anteroinferior in the posterior calcaneus (arrow)

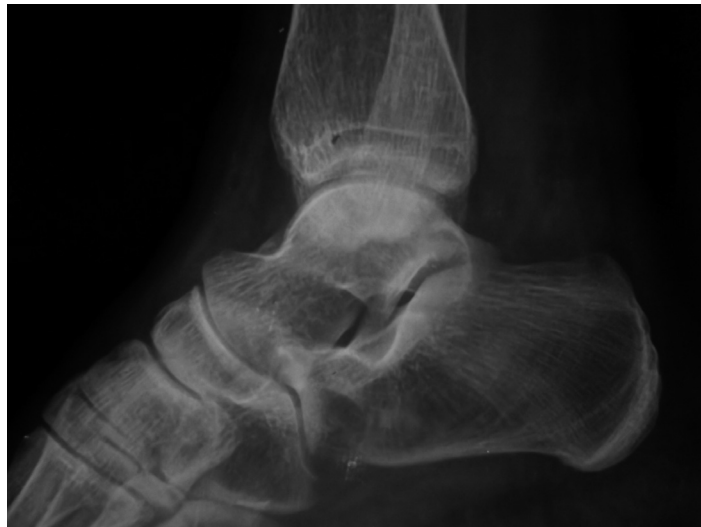

Fig. 2. Left lateral radiographs were unremarkable

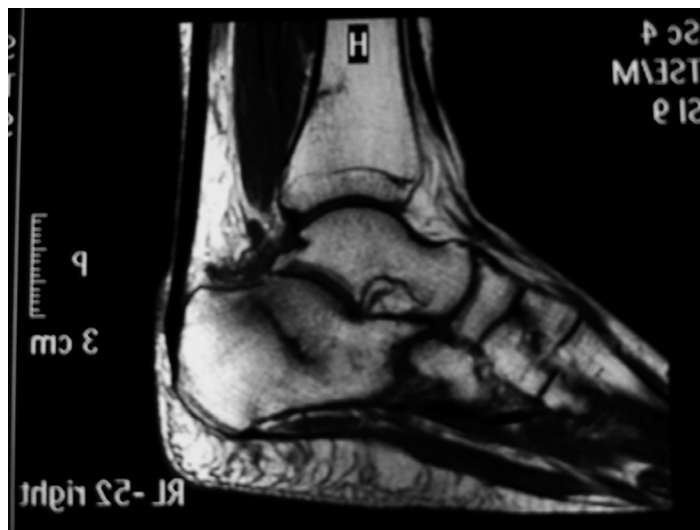

Fig. 3. (Right) Outlining a well-defined stress fracture line on T1 image. There is also decreased signal surrounding the fracture line, which represents marrow edema and inflammation

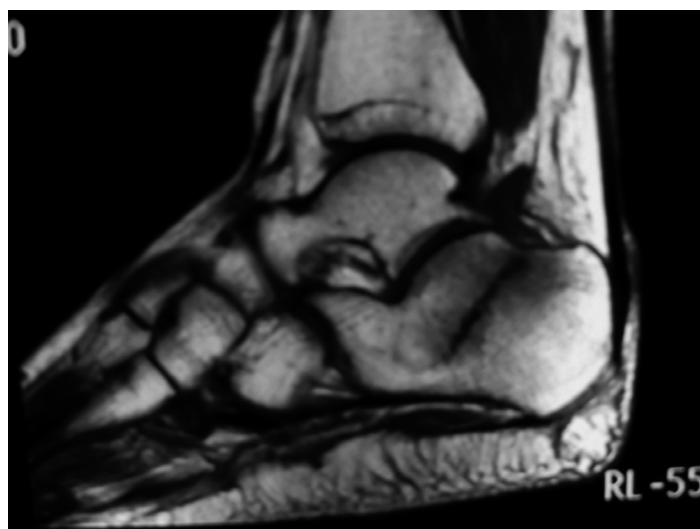


Fig. 4. (Left) Outlining a well-defined stress fracture line on T1 image. There is also decreased signal surrounding the fracture line, which represents marrow edema and inflammation

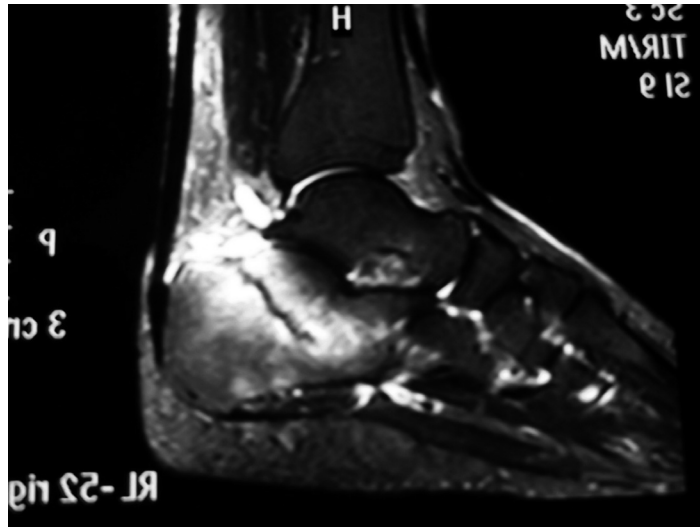


Fig. 5. (Right) Fracture line and marrow edema on T2 image. There is significant increase in signal intensity, which represents marrow edema

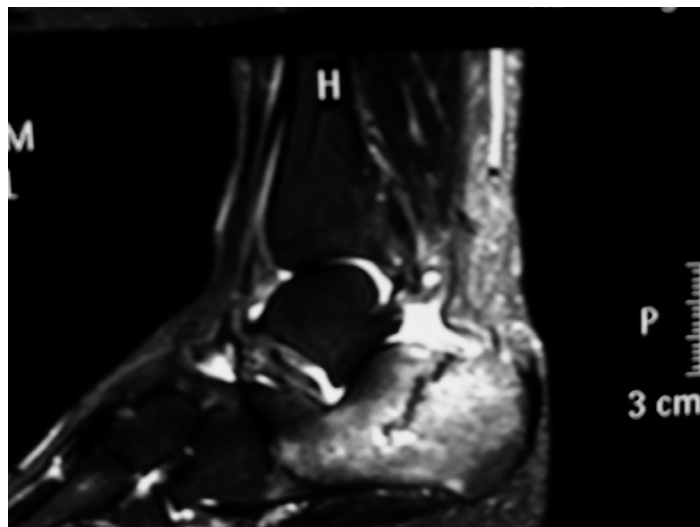


Fig. 6. (Left) Fracture line and marrow edema on T2 image. There is significant increase in signal intensity, which represents marrow edema

ted task for the clinician, as localized pain and tenderness to the posterior and/or plantar heel most often represent plantar fasciitis. Due to their relatively uncommon incidence when compared with these other stress fractures and other causes of heel pain, such as plantar fasciitis, they are often misdiagnosed or overlooked [1,12]. In general, progressive pain that begins insidiously after a change in shoe wear, activity level, or some other alteration of an individual's daily routine is one of the most common initial symptoms of a stress fracture [11,13].

There are two types of stress fractures: fatigue fractures and insufficiency fractures. Fatigue stress fractures are what most clinicians refer to when diagnosing a patient with a stress fracture. Fatigue stress fractures occur in normal bone that is subjected to

abnormal, repetitive stress [1,3,8]. Examples of fatigue fractures include stress fractures occurring in patients who have suddenly increased their activity levels, in military recruits undergoing basic training, and in patients with jobs that require them to walk or stand for extended periods of time on hard surfaces. The underlying mechanism here is that the patient's skeleton is subjected to an increased, uncharacteristic stress [11,13]. Our patient had a sedentary life style.

Insufficiency stress fractures are those that occur in abnormal, weak, or unhealthy bone. Examples of insufficiency fractures include stress fractures in patients with osteoporosis, a history of long-term corticosteroid therapy, diabetes mellitus, menstrual irregularity, osteoporosis, smoking and alcohol intake, hypothyroidism, anorexia nervosa, Paget disease, rhe-

umatoid arthritis, psoriatic arthritis, ankylosing spondylitis, thyroid disease, liver disease, and nutritional deficiencies [5,8]. The underlying mechanism with this type of stress fracture is that the underlying bone is weakened and/or diseased and is unable to withstand even normal physiologic stresses [1,11,13,14].

After the metatarsals, the calcaneus is the most common location in the foot for a stress fracture [8]. When one is treating bilateral calcaneal stress fractures, investigation into metabolic bone disease should be considered [12]. In our case metabolic bone diseases were not identified; however the erythrocyte sedimentation rate, routine hematologic and biochemical analysis as well as the rheumatological tests were in normal ranges. BMD was also in the normal range.

Physical examination typically reveals pain with medial to lateral compression of the heel. There may be pain with palpation of the plantar or posterior heel [1]. Despite the common practice of obtaining plain film radiographs in most patients who present with musculoskeletal pain in the foot or ankle, standard radiographs are usually not an effective imaging modality for visualizing stress fractures [10,14]. Both MRI and radionuclide bone scans detect stress frac-

tures several weeks earlier than is possible with standard radiographs [10,11]. Both methods have excellent sensitivity, but magnetic resonance imaging offers higher specificity and is considered to be the most sophisticated technology currently available with which to diagnose and describe bone stress injury [4,9,10, 15]. In our patient, a fracture line can be seen on the right lateral X-ray but on the left side the fracture line was unremarkable.

Calcaneal stress fractures are treated by reducing the quantity and intensity of walking and athletic activities. Non-weight-bearing status with crutches or cast immobilization may be necessary in some refractory cases [2,16,17].

### CONCLUSION

In this article, we focus on magnetic resonance imaging, which provides highly sensitive and specific evaluation for bone marrow edema, periosteal reaction as well as detection of subtle fracture lines. Plain radiography is useful when positive, but generally has low sensitivity. In a normal population, the possibility of calcaneal stress fractures must be borne in mind with patients who have bilateral heel pain.

### REFERENCES

1. Weber JM, Vidt LG, Gehl RS, Montgomery T. Calcaneal stress fractures. *Clin Podiatr Med Surg.* 2005;22:45-54.
2. Leabhart JW. Stress fractures of the calcaneus. *J Bone Joint Surg Am.* 1959;41-A:1285-90.
3. Arni D, Lambert V, Delmi M, Bianchi S. Insufficiency fracture of the calcaneum: Sonographic findings. *J Clin Ultrasound.* 2009;37:424-7.
4. Sormaala MJ, Niva MH, Kiuru MJ, Mattila VM, Pihlajamäki HK. Stress injuries of the calcaneus detected with magnetic resonance imaging in military recruits. *J Bone Joint Surg Am.* 2006;88:2237-42.
5. Aldridge T. Diagnosing heel pain in adults. *Am Fam Physician.* 2004;15;70:332-8.
6. Fredericson M, Jennings F, Beaulieu C, Matheson GO. Stress fractures in athletes. *Top Magn Reson Imaging.* 2006;17:309-25
7. Milgrom C, Giladi M, Stein M, Kashtan H, Margulies JY, Chisin R, Steinberg R, et al. Stress fractures in military recruits. A prospective study showing an unusually high incidence. *J Bone Joint Surg Br.* 1985;67:732-5.
8. Orhan Z, Parmaksizoglu A, Kayiran E. Calcaneal stress fractures in amateur football players. *Eur J Orthop Surg Traumatol.* 2000;10:133-135
9. Rosted A, Bang J, Svend-Hansen H. Bilateral stress-fracture of the calcaneal tubercle. *Acta Orthop Belg.* 1997;63:43-5.
10. Spitz DJ, Newberg AH. Imaging of stress fractures in the athlete. *Radiol Clin North Am.* 2002;40:313-31.
11. Dodson NB, Dodson EE, Shromoff PJ. Imaging strategies for diagnosing calcaneal and cuboid stress fractures. *Clin Podiatr Med Surg.* 2008;25:183-201.
12. Jeppesen KA, Palm H, Ebskov L. Missed stress fracture of the calcaneus. *Ugeskr Laeger.* 2009;171:2657-8.
13. Fishco WD, Stiles RG. Atypical heel pain. *J Am Podiatr Med Assoc.* 1999;89:413-8.
14. Hopson CN, Perry DR. Stress fractures of the calcaneus in women marine recruits. *Clin Orthop Relat Res.* 1977;128:159-62.
15. MacDonald RG. Early diagnosis and treatment of stress fractures of the calcaneus. *J Am Podiatry Assoc.* 1966;56:533-6.
16. Wentz L, Liu PY, Haymes E, Ilich JZ. Females have a greater incidence of stress fractures than males in both military and athletic populations: a systemic review. *Mil Med.* 2011;176:420-30.
17. Dixon S, Newton J, Teh J. Stress fractures in the young athlete: a pictorial review. *Curr Probl Diagn Radiol.* 2011;40:29-44.

Liczba słów/Word count: 1791

Tabele/Tables: 0

Ryciny/Figures: 6

Piśmiennictwo/References: 17

*Adres do korespondencji / Address for correspondence*

*Ahmet Imerci, Department of Orthopaedics and Traumatology,*

*Erzurum Palandoken State Hospital, 25000, Erzurum, Turkey*

*phone:+90 506 893 52 76 Fax; +90 442 235 41 00, e-mail; ahmet\_dr81@hotmail.com*

*Otrzymano / Received*

*04.04.2012 r.*

*Zaakceptowano / Accepted*

*09.07.2012 r.*