

Arthroscopic Tuberoplasty for a Malunited Greater Tuberosity Fracture: A Case Report

Maire-Clare Killen^{1(A,B,D,E,F)}, Charalambos P Charalambous^{1,2(A,E)}

¹ Orthopaedic Department, Blackpool Victoria Hospital, Whinney Heys Road, Blackpool, United Kingdom

² School of Medicine, University of Central Lancashire, Fylde Road, Preston, United Kingdom

SUMMARY

Superior migration and malunion of a fractured greater tuberosity can lead to mechanical subacromial impingement with resultant ongoing pain and limitation of abduction.

We describe such a case successfully treated with arthroscopic excision of the protruding portion of the greater tuberosity, with marked improvement in pain and range of movement. The greater tuberosity was exposed by elevating the supraspinatus tendon, which was reattached at the end of the procedure.

This case, along with outcomes of similar techniques previously reported in literature suggest that arthroscopic excision of a superiorly malunited greater tuberosity is associated with good symptomatic outcome and preservation of rotator cuff function.

Key words: shoulder; greater tuberosity; fracture; mal-union; arthroscopy

BACKGROUND

Fractures involving the greater tuberosity of the humerus are most commonly seen in complex proximal humeral fractures, but can also occur in isolation. Treatment of such cases is variable and often dependent on the degree of displacement or any associated injury to the shoulder.

Inadequate reduction or displacement can result in malunion of the greater tuberosity; in cases of superior migration this can result in mechanical subacromial impingement [1].

We describe a case of symptomatic impingement from malunion of the greater tuberosity following a three part proximal humeral fracture with successful treatment using arthroscopic excision of the prominent part of the greater tuberosity (tubero-plasty).

CASE REPORT

A 63-year-old female presented following a fall onto her right, dominant arm. Plain radiographs demonstrated a Neer three part proximal humeral fracture [2]. The patient was initially managed non-operatively.

Further radiographs two weeks later showed a superiorly displaced greater tuberosity. The patient had percutaneous cannulated screw fixation of the greater tuberosity, without adequate reduction (Fig. 1). Over the following nine months the patient noticed increasing pain and reduced range of movement of the right shoulder.

Arthroscopic subacromial decompression with excision of the coracoacromial ligament and antero-inferior acromioplasty was performed. The rotator

cuff was visualised from the subacromial space; it was intact and covering the greater tuberosity.

Four months later, abduction continued to be painful and limited (to a maximum of 60 degrees).

Due to the ongoing symptoms, further arthroscopic surgery was performed. Examination under anaesthesia and radiographic screening of the shoulder in the operating theatre revealed mechanical impingement due to a malunited greater tuberosity (Fig. 2).

Whilst visualising the subacromial space through a posterior portal, the supraspinatus tendon was elevated from the greater tuberosity using electrocautery. This exposed the malunited greater tuberosity which, following removal of the cannulated screw, was excised to a level in line with the superior part of the articular surface of the humeral head. Tubero-plasty was carried out via a lateral working portal. The elevated supraspinatus tendon was then reattached to the tuberosity bed using with a suture anchor that was loaded with two pairs of sutures (5 mm Fastin, Mitek UK). The elevated tendon was visualised through the lateral portal with anterior and posterior working portals employed. A single row technique was used. One pair of sutures was passed through the anterior part of the tendon with the other pair passed through the posterior part in a horizontal mattress-like configuration. Arthrolysis of the rotator interval was also performed. There was no impingement on abduction during immediate post-operative screening. A post-operative radiograph is shown in Fig. 3.

Nine months post-operatively, a marked improvement in range of movement was evident; forward flexion had increased by 30 degrees and the range of

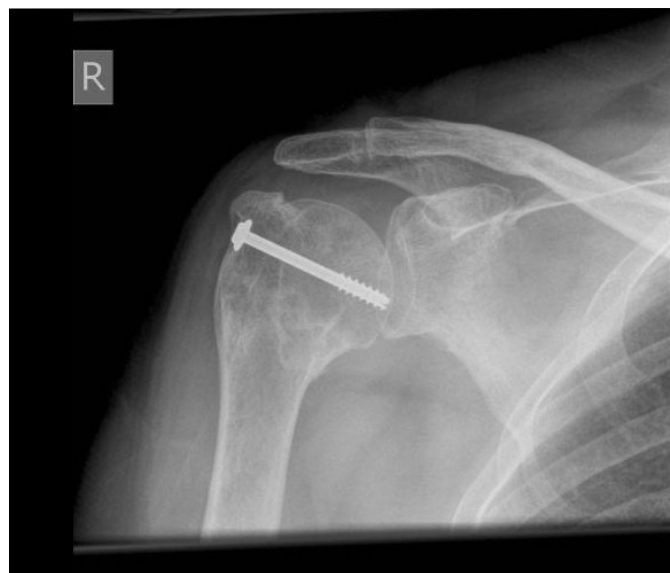

Fig. 1. Initial post-operative radiograph following cannulated screw fixation of the greater tuberosity without adequate reduction; the tuberosity is malunited in a superiorly migrated position

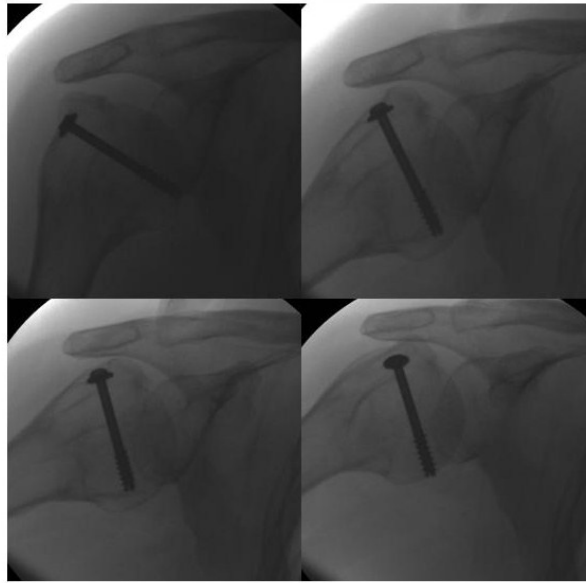


Fig. 2. Intra-operative screening radiographs demonstrating a mechanical block to abduction due to the greater tuberosity

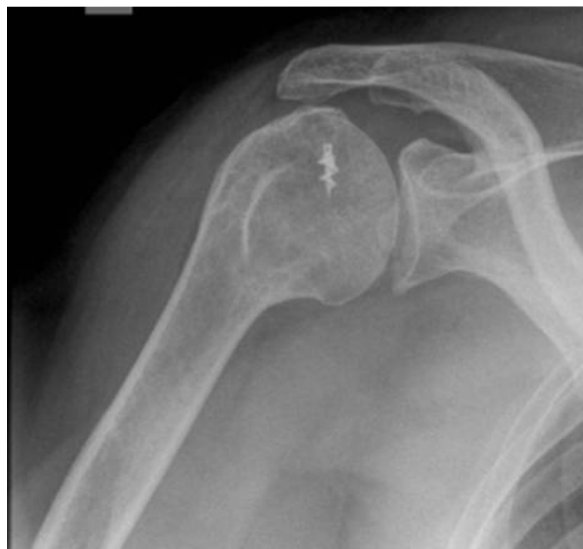

Fig. 3. Post-operative radiograph showing improved joint contour following arthroscopic tuberoplasty

abduction had markedly improved from a maximum of 60 degrees pre-operatively to 110 degrees post-operatively.

Strength of the rotator cuff muscles was normal (Oxford score 5/5 for supraspinatus, infraspinatus and subscapularis). Impingement and scarf tests were negative.

The patient complained of some pain at the extremes of abduction, which fully resolved following a subsequent intra-articular steroid injection.

The Oxford Shoulder questionnaire, completed fourteen months post-operatively, revealed minimal functional impairment and satisfactory joint function with a score of 41 out of 48.

DISCUSSION

The greater tuberosity is situated approximately 8 mm inferior to the most superior portion of the humeral head. The complex geometry of the greater tuberosity and rotator cuff tendons permits effective rotator cuff and deltoid function, as well as clearance through the subacromial space [3].

When the greater tuberosity is displaced more than 5 mm, subacromial impingement usually occurs with subsequent limitation of abduction and external rotation; the deltoid force required to perform abduction is greatly increased with this degree of displacement [3,4]. Malunion of the greater tuberosity in

a superiorly migrated position is a challenging problem to treat.

Previously, treatment for malunion of proximal humeral fractures has been described via an open approach, in the form of corrective osteotomy with reposition and fixation of the fragment. There are limited reports regarding this treatment option, but it has been found to be a technically demanding procedure [5,6].

More recently, arthroscopic management has been described as a viable treatment option, allowing better visualisation and mobilisation of the malunited fragment, with the additional benefit of being able to identify and treat any associated intra-articular and rotator cuff pathology [7,8].

A small number of reports have been published describing procedures involving arthroscopic excision of the malunited greater tuberosity to treat subacromial impingement, reporting positive outcomes.

In 2002, Porcellini et al reported a case of posterior malunion of the greater tuberosity impinging on the glenoid surface, causing a mechanical block to internal rotation of the shoulder. This was successfully treated with removal of the impinging bone arthroscopically with complete resolution of symptoms [9].

Following this, Ji et al reported the first case of an all-arthroscopic technique for treatment of a postero-superiorly displaced malunited greater tuberosity fragment using osteotomy and fixation with suture anchors [10]. In contrast to our procedure, the authors

described visualisation and debridement of the malunited fragment, with subsequent detachment of this fragment using an osteotome. The fragment was then reduced into its anatomical position and reattached using a suture-bridge fixation technique, while remaining incorporated into the intact rotator cuff. Complete symptomatic relief and normal range of movement was reported one year post-operatively.

Martinez et al carried out a small case series of eight patients with malunion of the greater tuberosity [11]. In all cases, the rotator cuff was detached from its insertion to the greater tuberosity with electrocautery. The greater tuberosity was reshaped using a power burr with subsequent reattachment of the rotator cuff with suture anchors, using a double row technique. Here, as in our case, all patients had symptomatic improvement and restoration of rotator cuff power.

Slight displacement of the greater tuberosity following fracture can cause substantial symptoms requiring surgical intervention. In cases where there is malunion of the greater tuberosity with superior displacement causing symptomatic subacromial impingement, arthroscopy should be considered as an effective treatment option. The technique of elevation of the rotator cuff, arthroscopic tuberoPlasty with reattachment of supraspinatus using bony anchors provides a minimally invasive solution for successfully relieving symptoms, without majorly compromising rotator cuff function.

REFERENCES

1. George MS. Fractures of the Greater Tuberosity of the Humerus. *J Am Acad Orthop Surg* 2007; 15: 607-13.
2. Neer CS 2nd. Displaced proximal humeral fractures. I. Classification and evaluation. *J Bone Joint Surg Am* 1970; 52(6): 1077-89.
3. Iannotti JP, Gabriel JP, Schneck SL, et al. The normal glenohumeral relationships: An anatomical study of one hundred and forty shoulders. *J Bone Joint Surg Am* 1992; 74: 491-500.
4. Bono CM, Renard R, Levine RG, et al. Effect of displacement of fractures of the greater tuberosity on the mechanics of the shoulder. *J Bone Joint Surg Br* 2001; 83(7): 1056-62.
5. Beredjiklan PK, Iannotti JP. Treatment of proximal humerus fracture malunion with prosthetic arthroplasty. *Instr Course Lect* 1998; 47: 135-40.
6. Cheung EV, Sperling JW. Management of proximal humeral non unions and malunions. *Orthop Clin N Am* 2008; 39: 475-82.
7. Song HS, Williams GR. Arthroscopic reduction and fixation with suture bridge technique for displaced or comminuted greater tuberosity fractures. *Arthroscopy* 2008; 24(8): 956-60.
8. Romanowski L, Manikowski W, Szałowski R, Lubiawski P. Impingement and rotator cuff lesion an arthroscopic treatment. *Ortop Traumatol Rehabil* 2003; 5(4): 457-62.
9. Porcellini G, Campi F, Paladini P. Articular impingement in malunited fracture of the humeral head. *Arthroscopy* 2002; 18(8): E39.
10. Ji JH, et al. Arthroscopic fixation for a malunited greater tuberosity fracture using the suture-bridge technique: technical report and literature review. *Knee Surg Sports Traumatol Arthrosc* 2009; 17: 1473-6.
11. Martinez AA, et al. Arthroscopic treatment for malunions of the proximal humeral greater tuberosity. *International orthopaedics* 2010; 34: 1207-11.

Liczba słów/Word count: 1493

Tabele/Tables: 0

Ryciny/Figures: 3

Piśmiennictwo/References: 11

Adres do korespondencji / Address for correspondence

Miss Maire-Clare Killen

Orthopaedic Department, University Hospital North Tees Stockton-on-Tees,
TS19 8PE, phone: 07736934388, e-mail: maire-clare.killen@doctors.org.uk

Otrzymano / Received

26.05.2015 r.

Zaakceptowano / Accepted

02.11.2015 r.