

Exercise and Therapeutic Ultrasound Compared with Corticosteroid Injection for Chronic Lateral Epicondylitis: A Randomized Controlled Trial

Ardiana Murtezani^{1(A,B,C,D,E,F)}, Zana Ibraimi Pharm^{2(C,D,F)}, Teuta Osmani Vllasolli^{1(A,B,E)},
Sabit Sllamniku^{3(A,C,D)}, Shaip Krasniqi^{4(B,C,D,E)}, Lulzim Vokrri^{5(E,F)}

¹ Physical and Rehabilitation Medicine Clinic, University Clinical Center of Kosovo, Prishtina, Kosovo

² Department of Pharmacy, Faculty of Medicine, University of Kosovo

³ Orthopedic and Traumatic Clinic, University Clinical Center of Kosovo

⁴ Department of Pharmacology, Faculty of Medicine, University of Kosovo

⁵ Department of Vascular Surgery, University Clinical Center of Kosovo

SUMMARY

Background. Lateral epicondylitis, or tennis elbow, is a common overuse syndrome of the extensor tendons of the forearm. When the condition is chronic or not responding to initial treatment, physical therapy is initiated. The objective of this study is to compare the effectiveness of corticosteroid injections with physiotherapeutic interventions (ultrasound and exercise) for the treatment of chronic lateral epicondylitis.

Material and methods. We performed a randomized controlled trial of 12 weeks' duration in patients with chronic lateral epicondylitis. We randomly assigned 49 subjects to an exercise group (n=25), who received ultrasound and exercise, and a control group (n=24), who were treated with local infiltration of 1mL triamcinolone acetonide (10mg/mL) and 1mL lidocaine 2%. To evaluate the subjects, three instruments were used: pain intensity, measured with a Visual Analogue Scale (VAS), functional disability, measured with the Patient-Rated Tennis Elbow Evaluation (PRTEE) questionnaire, and painfree grip strength. All subjects were evaluated before treatment and at the 6th and 12th week.

Results. There were no significant differences between the two groups with regard to any variable at baseline (p>0.05). In the exercise group, significant improvements were demonstrated for VAS, PRTEE pain score, PRTEE function score and pain free grip strength, compared to the control group. The exercise group reported a significantly greater increase in all variables at 12 weeks than did the control group (p<0.001).

Conclusion. Our results suggest that ultrasound therapy and exercise are beneficial in the treatment of tennis elbow.

Key words: lateral epicondylitis, ultrasound therapy, exercise, corticosteroid injection, treatment

BACKGROUND

Lateral epicondylitis, or tennis elbow, is a common overuse syndrome of the extensor tendons of the forearm causing pain in the elbow and forearm and lack of strength and function of the elbow and wrist [1,2]. It is a common disorder with a prevalence of at least 1.7% [3,4]. The condition affects men and women equally, occurring most often between the third and sixth decades of life with a peak occurrence in the fifth decade [5].

A multitude of treatment options are available to reduce symptoms and to attempt to stimulate or enhance the tendon healing response. Initially, lateral epicondylitis can be treated with rest, ice, bracing, and non-steroidal anti-inflammatory drugs (NSAIDs), administered either orally or topically [1]. However, when the condition is chronic or does not respond to initial treatment, physical therapy is initiated. Various rehabilitation modalities, such as ultrasound, phonophoresis, electrical stimulation, laser, extracorporeal shock wave therapy, electromagnetic field therapy, manipulations and mobilizations, friction massage, acupuncture, and stretching and strengthening exercises, have been found to provide short-term benefit or do not appear to be effective in the reduction of pain or improvement in function for patients with lateral epicondylitis [2,3,6,7].

Patients may benefit from surgical intervention when conservative strategies fail to relieve lateral epicondylitis symptoms after six to 12 months [2].

Physical therapy regimens, including strength training and stretching, are commonly used to treat lateral epicondylitis. Evidence suggests that exercise programs can reduce pain, but the improvement in grip strength is less clear [3,8,9]. Exercise therapy and stretching exercises have been used either alone or in conjunction with physical interventions [10].

Local corticosteroid injection provides short-term benefit in pain reduction and grip strength compared with other conservative treatments [11,12]. Several studies have found that long-term effectiveness of corticosteroid injections and their advantages over other conservative treatments are uncertain [11-13].

The objective of this study was to compare the effectiveness of corticosteroid injections with physiotherapeutic interventions, US and exercise for the treatment of lateral epicondylitis (tennis elbow).

MATERIAL AND METHODS

Study design

We performed a randomized, double-blind, controlled trial of 12 weeks' duration in patients with

chronic lateral epicondylitis. The trial was conducted at the Clinic of Physical and Rehabilitation Medicine of the University Clinical Center of Kosovo. All subjects gave written informed consent before entering the study. The study was approved by the Ethical Board of the Faculty of Medicine, University of Prishtina.

Subjects

The study population consisted of subjects with a clinical diagnosis of lateral epicondylitis. Participants were enrolled over 9 months: of a group of 77 patients referred by general health practitioners, orthopedists, and rheumatologists 49 were finally included to in the trial. During the initial visit, subjects were assessed for their suitability, including demographic information and baseline measurements.

Eligible participants were of both sexes, over 18 years of age, with lateral elbow pain for more than 3 months with a verified diagnosis of tennis elbow. The diagnosis was based on a history of lateral elbow pain and tenderness over the forearm extensor origin and pain increasing on resisted middle finger extension and resisted wrist extension with the elbow extended. Exclusion criteria comprised: carpal or radial tunnel syndrome, cervical radiculopathy, painful shoulder or rotator cuff tendinitis, inflammatory joint disease, trauma to the affected elbow in the past 6 weeks, bilateral elbow symptoms, contraindications for corticosteroid use and previous elbow surgery.

A total of 49 patients with tennis elbow lasting for more than 3 months were randomly allocated to a physiotherapeutic group ($n = 25$) or a corticosteroid injection group ($n = 24$).

Randomisation

The patients who had consented to participate in the study were randomly allocated in accordance with recognized procedures by computer-generated random allocation sequences that were prepared centrally by the trial statistician. The assessor was blinded to the allocation of participants to the treatment groups.

Intervention

The subjects assigned to the corticosteroid injection group were treated by an orthopedist with local infiltration of 1mL triamcinolone acetonide (10mg/mL) and 1mL lidocaine 2%. Local corticosteroid injection was administered to the most painful area on pressure around the lateral epicondyle. During the six-week intervention period, a maximum of two injections was recommended.

Subjects were advised not to use the affected arm for any activity which provoked pain during the six weeks of the treatment period.

The subjects assigned to the physiotherapy group received 18 sessions of ultrasound therapy and an exercise programme over 6 weeks. The ultrasound (Medio SONO, Iskra Medical, Slovenia) treatment was applied in a pulsed mode with a 20% duty cycle, intensity of 1.5 w/cm², frequency of 1MHz, for 5 to 7 minutes on three days a week for 6 weeks [14]. The exercise treatment consisted of progressive, slow, repetitive wrist and forearm stretching, muscle conditioning, and occupational exercise administered in four steps of increasing intensity two times daily on three days a week for 6 weeks [10]. One treatment session lasted 50 minutes.

The treatment for each group was continued for six weeks, during which time they received no other treatment.

Outcome measures

The subjects were interviewed using a structured questionnaire which included information regarding the following individual characteristics: age, weight, height, educational level, smoking habits, TE history, and previous treatment given during the current episode.

To evaluate the subjects, three instruments were used: pain intensity, measured by the Visual Analogue Scale (VAS), functional disability, measured by the Patient-Rated Tennis Elbow Evaluation (PRTEE) questionnaire, and painfree grip strength [15-17].

On the basis of current literature we assumed a 50% improvement from baseline in elbow pain or function to represent clinically important change [18].

The Visual Analogue Scale

A Visual Analogue Scale (VAS) was used to measure pain intensity during rest. The level of pain was recorded on a 10 cm line where 0 was classified as "no pain" and 10 was classified as "worst possible pain". Subjects were asked to indicate their pain level by placing a mark along this horizontal line [15].

Patient-Rated Tennis Elbow Evaluation questionnaire

The Patient-Rated Tennis Elbow Evaluation (PRTEE) questionnaire is an instrument that has been developed specifically for use with this disorder [16]. It takes the form of a 15-item questionnaire, with five items addressing pain and 10 concerned with functional deficit. For each item, the respondent uses a 0-10 numerical scale to rate the average pain or difficulty they have experienced over the previous week while carrying out various activities that are commonly painful in tennis elbow. The marking system ensures that pain and function are weighted equally

in the total score. Higher scores represent greater severity and the maximum score is 100 [19].

The pain free grip strength

The pain free grip strength (GS) of the affected hand was measured using a hand-held dynamometer (Hand Force, ANG 2010/01, Iskra Medical, Ljubljana, Slovenia) [17]. Muscle strength of the forearm extensor muscles was also measured at all visits. All of the outcomes were measured at baseline and at follow-up visits at 6, and 12 weeks of treatment by the same blinded assessor.

Statistical analysis

All hypothesis tests were two-tailed and a *P*-value of 0.05 was considered statistically significant. Differences from the baseline values were compared for both treatment groups at 6 and 12 weeks. The analyses were carried out according to a protocol. Continuous data were compared between groups using the Mann-Whitney U-test and categorical data, with Fisher's exact test. Analyses were carried out with SPSS version 12.0 (available at www.spss.com). Absolute and percentage changes in the PRTEE total and subscale scores between the assessments were calculated. The data analyses included only those participants who had completed the 6-week interventional period.

RESULTS

A total of 77 subjects were screened: 60 entered the trial. Eleven subjects (5 from the exercise group and 6 from the control group) withdrew spontaneously for medical and personal reasons after randomization: difficulties in transportation (*n*=2), "got better" (*n*=2), low back pain (*n*=1), personal reason (*n*=2), commenced physiotherapy (*n*=2) and unreachable (*n*=2). Adherence to the exercise group was 82%. Forty-nine subjects (28 men, 21 women, mean age 51.3±6.4 years) completed the study. Figure 1 shows a flow diagram of subject progression through the study.

Table 1 describes the demographic and medical characteristics of the 49 subjects who completed the study. Overall, the two groups were similar at baseline. No significant differences were found between the groups for any variable (*p*>0.05). All had been treated in different ways before entering the study.

Table 2 summarizes the outcome variables measured at baseline and during the 6 and 12 weeks' postintervention assessment separately for the exercise and control group. There were no significant differences between the two groups in the baseline values for the VAS, PRTEE pain score, PRTEE function score and grip strength (*p*>0.05).

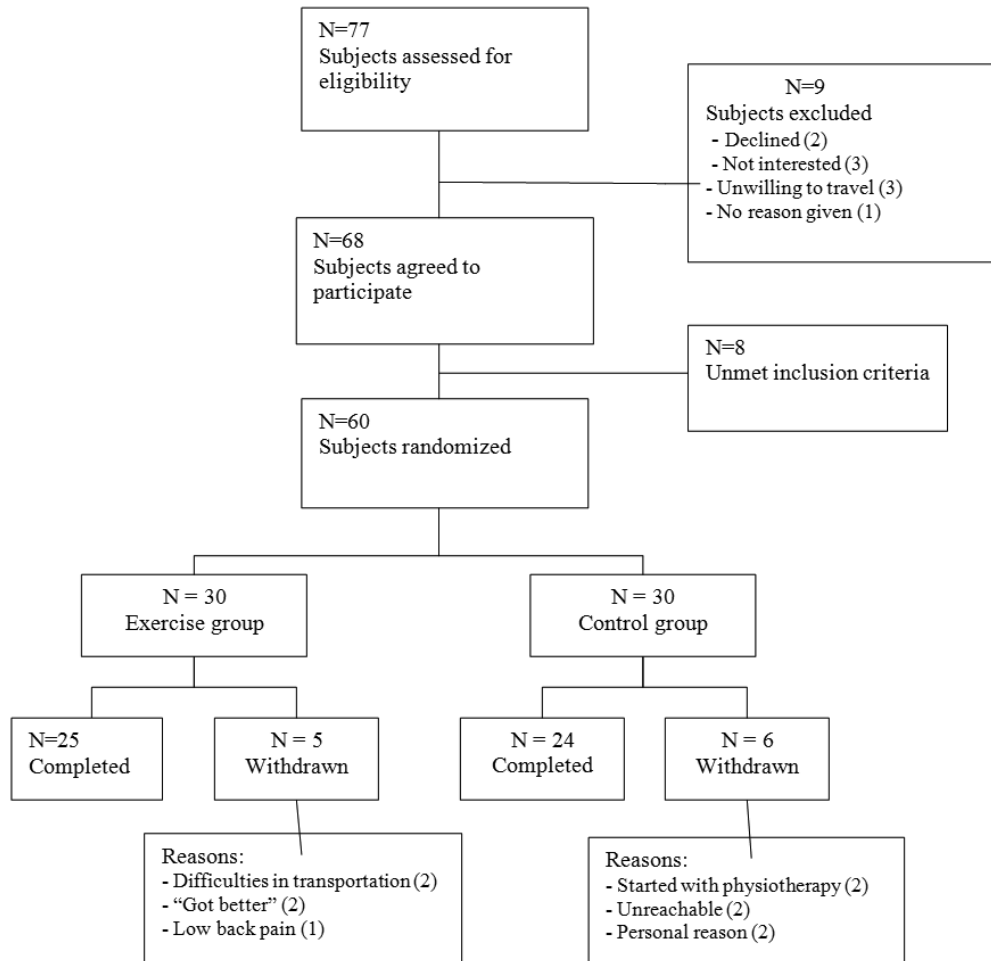


Fig. 1. Flow of participants through the trial

Tab. 1. Baseline characteristics

Characteristic	Overall (n=49)	Exercise Group (n=25)	Control Group (n=24)	p ¹
Age, years	51.3 ± 6.4	51.6 ± 6.7	51 ± 6.2	0.716
Gender				0.332
Male	28 (57%)	16 (64%)	12 (50%)	
Female	21 (43%)	9 (36%)	12 (50%)	
Completed university	19 (38%)	11 (44%)	8 (33%)	0.454
Smokers	20 (40%)	8 (32%)	12 (50%)	0.200
Weight, kg	77.2 ± 8.2	79.3 ± 8.7	75.1 ± 7.4	0.080
Height, cm	173.4 ± 6.1	174.0 ± 6.3	172.8 ± 6.0	0.515
Previous management of condition				
NSAID	41 (84%)	25 (100%)	16 (67%)	
Topical NSAID	21 (43%)	13 (52%)	8 (33%)	
Corticosteroid injection	16 (33%)	9 (36%)	7 (29%)	
Physiotherapy	11 (22%)	5 (20%)	6 (25%)	
Orthosis	10 (20%)	6 (24%)	4 (17%)	
Pain duration (months)	12.9 ± 7.0	12.2 ± 5.5	13.6 ± 8.4	0.497
Arm dominance		23 Right, 2 Left	23 Right, 1 Left	0.581
Symptomatic arm		18 Right, 7 Left	18 Right, 6 Left	0.816
No. of dominant arm symptomatic		20 (80%)	19 (79%)	

Note 1: Data for continuous variables are presented as mean ± SD

Note 2: Data for categorical variables are presented as frequency(percentage)

¹ P value from one-way ANOVA for the difference between groups.

Tab. 2. Effect of Interventions on outcome parameters

Variable	BT		6 weeks AT		12 weeks AT	
	mean ± SD	p ¹	mean ± SD	p ²	mean ± SD	p ²
<i>Visual Analogue Scale (VAS)</i>						
Exercise group	5.0 ± 1.2		3.1 ± 1.1	0.001	1.8 ± 0.9	0.001
Control group	5.4 ± 1.0	0.117	2.5 ± 0.8	0.001	2.9 ± 0.9	0.001
<i>PRTEE Pain Score (PS)</i>						
Exercise group	24.9 ± 9.9		14.2 ± 5.8	0.001	16.3 ± 5.2	0.001
Control group	21.9 ± 9.2	0.272	8.4 ± 3.5	0.001	14.9 ± 3.7	0.001
<i>PRTEE Function Score (FS)</i>						
Exercise group	23.9 ± 9.2		14.6 ± 5.5	0.001	16.0 ± 5.3	0.001
Control group	28.3 ± 10.5	0.129	12.2 ± 6.4	0.001	17.7 ± 4.6	0.001
<i>Grip strength (GS)</i>						
Exercise group	33.0 ± 9.3		40.6 ± 9.0	0.001	37.8 ± 9.4	0.001
Control group	30.0 ± 9.7	0.277	40.2 ± 9.7	0.001	34.5 ± 9.4	0.001

Exercise group (n = 25); control group (n= 24).

BT - before treatment; AT - after treatment

¹ P value for difference between groups with one-way ANOVA

² P value for change after training from before training with one-way ANOVA

The mean scores of VAS, PRTEE pain, PRTEE function, and grip strength improved significantly ($p < 0.001$) in both groups at the 6th-, and 12th-week assessment compared with the baseline score. However, the best VAS, PRTEE pain, PRTEE function, and grip strength scores were seen at 6 weeks in both groups.

Comparison between the two groups confirmed that at six weeks the injection group was significantly better than the exercise group in VAS, PRTEE pain, PRTEE function and grip strength. However, these differences were no longer evident by 12 weeks, when the exercise group was significantly better in all parameters.

DISCUSSION

In our study lateral elbow pain and functional disability showed significant improvement in both groups during a 12-week period, specifically being greater in the control group after 6 weeks, but lasting more in the exercise group.

This finding is in line with previous reviews, where the authors concluded that corticosteroid injections were effective in the short term and that physiotherapeutic interventions were effective in the intermediate and long term in treating patients with lateral epicondylitis (tennis elbow), although these conclusions should be interpreted with caution, due to the limited evidence presented [11,13,20-24].

There are contradictions in various scientific papers on the type of treatment concerning TE subjects [3,5,20,25]. Results from randomized controlled trials have been conflicting. Although there is a growing recognition of the importance of exercise therapy in the management of tendinopathies [10,25-28], most studies concluded that it is still unclear whether

exercise therapy is more effective than inactive treatment [4,5].

Newcomer et al. believe that rehabilitation should be the primary therapeutic means for patients with tennis elbow, as the corticosteroid injections do not provide clinically significant and lasting improvement [23]. In concordance with this, the results of three other trials suggest that corticosteroid injections offer the best prospects for short term relief of symptoms, and physiotherapy (perhaps the exercise component of physiotherapy) offers the best prospect for good long-term outcomes [11,13,20].

Recent years have seen a growing interest in exercise as treatment for chronic tendinopathies [10, 28]. A few recent studies have reported a clear tendency in favor of exercise as compared with expectation [26,28]. Likewise, a study done in 81 subjects with TE concluded that chronic TE should not be treated with rest but with graded exercise [26]. This is in line with the findings of pain psychologists, who point out the negative effects of inactivity and related fear avoidance behavior and suggest graded activity as a means of overcoming this problem [27].

In our study, in the exercise group we have combined exercises with ultrasound therapy and have gained significant improvement after 6 weeks that, however, also continued even after 12 weeks. The finding was in agreement with other studies which included combinations of various physical therapy modalities, albeit reaching conflicting results [3,5, 14,25,29-32].

Latala et al. compared the effectiveness of three methods of physical therapy: iontophoresis, phonophoresis, and low frequency magnetic field, on epicondylitis treatment [25]. They concluded that all these

types of therapy offer benefits in epicondylitis and the methods can be used alternatively as none of them were superior to the rest.

23 RCTs were included in a review evaluating the effects of laser therapy, ultrasound treatment, electrotherapy, and exercises and mobilisation techniques [3]. Weak evidence for efficacy was only found for ultrasound. In another study, the authors administered low level laser therapy directly to the lateral elbow tendon insertions, offering short-term pain relief and less disability in TE [5].

Binder and colleagues reported significantly improved recovery in patients with TE treated with ultrasound compared with those treated with sham ultrasound [14]. In contrast to the positive findings of this study, Haker and co-workers and Lundeborg and colleagues reported no significant difference in the healing of lateral epicondylitis between ultrasound-treated groups and sham ultrasound-treated groups using either continuous or pulsed ultrasound [30,31].

Due to heterogeneity of the studies, small sample sizes, variety of treatment strategies used, and the application of treatment at different stages of healing, it is difficult to recommend any particular intervention over others. As of yet, no optimal strategy has been identified. Therefore, further research efforts are needed to determine which method is more effective.

REFERENCES

1. Cochrane Database of Systematic Reviews: Non-steroidal anti-inflammatory drugs (NSAIDs) for treating lateral elbow pain in adults; 2001.
2. Johnson GW, Cadwallader K, Scheffel SB, Epperly TD. Treatment of lateral epicondylitis. *Am Fam Physician*. 2007; 76(6): 843-8.
3. Smidt N, Assendelft JJ, Arola H, Malmivaara, A et al. Effectiveness of physiotherapy for lateral epicondylitis: a systematic review. *Ann Med* 2003, 51-62.
4. Shiri R, Viikari-Juntura E, Varonen H, Heliövaara M. Prevalence and determinants of lateral and medial epicondylitis: a population study. *Am J Epidemiol*. 2006; 164(11): 1065-74.
5. Bjordal JM, Lopes-Martins RAB, Joensen J, et al. A systematic review with procedural assessments and meta-analysis of Low Level Laser Therapy in lateral elbow tendinopathy (tennis elbow). *BMC Musculoskeletal Disorders* 2008; 9: 75.
6. Trudel D, Duley J, Zastrow I, Kerr E W, Davidson R, MacDermid J C. Rehabilitation for patients with lateral epicondylitis: a systematic review. *Journal of Hand Therapy* 2004; 17(2): 243-66.
7. Andres BM, Murrell GAC. Treatment of Tendinopathy: What works, what does not, and what is on the horizon. *Clinical Orthopaedics and Related Research*. 2008; 466(7): 1539-54.
8. Croisier JL, Dessalle MF, Tinant F, Crielaard JM, Forthomme B. An isokinetic eccentric programme for the management of chronic lateral epicondylar tendinopathy. *Br J Sports Med*. 2007; 41(4): 269-75.
9. Rompe JD, Maffulli N. Repetitive shock wave therapy for lateral elbow tendinopathy (tennis elbow): a systematic and qualitative analysis. *Br Med Bull* 2007; 83: 355-78.
10. Pienimäki TT, Tarvainen TK, Siira PT, Vanharanta H. Progressive Strengthening and Stretching Exercises and Ultrasound for Chronic Lateral Epicondylitis. *Physiotherapy* 1996; 82(9): 522-30.
11. Smidt N, Assendelft WJ, Windt DA, Hay EM, Buchbinder R, Bouter LM. Corticosteroid injections for lateral epicondylitis: a systematic review. *Pain* 2002; 96(1-2): 23-40.
12. Assendelft W, Green S, Buchbinder R, Struijs P, Smidt N. Tennis elbow. *Clin Evid*. 2004; (11): 1633-44.
13. Smidt N, van der Windt DA, Assendelft WJ, Deville WL, Korthalsde Bos IB, Bouter LM. Corticosteroid injections, physiotherapy, or a wait-and-see policy for lateral epicondylitis: a randomised controlled trial. *Lancet* 2002; 359: 657-62.
14. Binder A, Hodge G, Greenwood AM, Hazelman BL, Page Thomas DP. Is therapeutic ultrasound effective in treating soft tissue lesions? *British Medical Journal* 1985; 290: 512-4.

This study had several strengths, e.g. its randomized controlled design. According to the subjects' characteristics at baseline, our subjects were similar and corresponded to those participating in other similar studies [10,13,29]. The subjects' adherence to the treatment programme was satisfactory and we had a low rate of loss to follow-up.

A few limitations should be noted. This study utilized a small sample. Long-term outcomes were not evaluated in these subjects so it cannot be determined if the effect of treatment can be maintained over time.

CONCLUSION

1. Combined 6-week programme of exercises with ultrasound therapy showed improvement in pain and function among subjects with TE.
2. In future studies we should evaluate the efficacy of similar programs and exercises with other physical therapy modalities during a longer time span and involving a larger number of patients.

ACKNOWLEDGEMENT

We would like to thank GEN Daniel J. Dire (MC, US Army Res) for providing helpful suggestions and reviewing this manuscript.

15. Huskisson EC, Jones J, Scott PJ. Application of visual-analogue scales to the measurement of functional capacity. *Rheumatology* 1976; 15(3): 185-7.
16. MacDermid J. Update: The Patient-rated Forearm Evaluation Questionnaire is now the Patient-rated Tennis Elbow Evaluation. *J Hand Ther* 2005; 18: 407-10
17. Roberts HC, Denison HJ, Harnish MP, et al. A review of the measurement of grip strength in clinical and epidemiological studies: towards a standardised approach. *Age Ageing*. 2011; 40(4): 423-9.
18. Poltawski L, Watson T. Measuring clinically important change with patient-rated tennis elbow evaluation. *Hand Therapy* 2011; 16: 52-7.
19. MacDermid J. The Patient-Rated Tennis Elbow Evaluation (PRTEE) User Manual. Hamilton, Canada: School of Rehabilitation Science, McMaster University; 2007.
20. Bisset L, Paungmali A, Vicenzino B, Beller E. A systematic review and meta-analysis of clinical trials on physical interventions for lateral epicondylalgia. *Br J Sports Med* 2005; 39: 411-22.
21. Barr S, Cerisola FL, Blanchard V. Effectiveness of corticosteroid injections compared with physiotherapeutic interventions for lateral epicondylitis: a systematic review. *Physiotherapy* 2009; 95(4): 251-65.
22. Stasinopoulos DI, Johnson MI: Effectiveness of low-level laser therapy for lateral elbow tendinopathy. *Photomed Laser Surg* 2005; 23(4): 425-30.
23. Newcomer KL, Laskowski ER, Idank DM, McLean TJ, Egan KS. Corticosteroid Injection in Early Treatment of Lateral Epicondylitis. *Clinical Journal of Sport Medicine* 2001; 11(4): 214-22.
24. Tonks JH, Pai SK, Murali SR. Steroid injection therapy is the best conservative treatment for lateral epicondylitis: a prospective randomized controlled trial. *Int J Clin Pract* 2007; 61(2): 240-6.
25. Latala B, Mosurska D, Otfinowski J, Regula K. Physical therapy in treatment of lateral and medial epicondylitis. *Fizjoterapia* 2009; 17(1): 3-10.
26. Peterson M, Butler S, Eriksson M, Svärdsudd K. A randomized controlled trial of exercise versus wait list in chronic tennis elbow (lateral epicondylitis). *Ups J Med Sci*. 2011; 116(4): 269.
27. Vlaeyen JW, Linton SJ. Fear-avoidance and its consequences in chronic musculoskeletal pain: a state of the art. *Pain* 2000; 85: 317-32.
28. Bisset L, Beller E, Jull G, Brooks P, Darnell R, Vicenzino B. Mobilisation with movement and exercise, corticosteroid injection, or wait and see for tennis elbow: randomised trial. *BMJ* 2006; 333(7575): 939.
29. D'Vaz AP, Ostor AJK, Speed CA, et al. Pulsed low-intensity ultrasound therapy for chronic lateral epicondylitis: a randomized controlled trial. *Rheumatology* 2006: 566-70.
30. Haker E, Lundeberg T. Pulsed ultrasound treatment in lateral epicondylitis. *Scand J Rehab Med* 1991; 23: 115-8.
31. Lundeberg T, Abrahamsson P, Haker E. A comparative study of continuous ultrasound, placebo ultrasound and rest in epicondylalgia. *Scand J Rehabil Med* 1988; 20: 99-101.
32. Uzunca K, Birtane M, Tastekin N. Effectiveness of pulsed electromagnetic field therapy in lateral epicondylitis. *Clin Rheumatol* 2007; 26: 69-74.

Liczba słów/Word count: 3435

Tabele/Tables: 2

Ryciny/Figures: 1

Piśmiennictwo/References: 32

Adres do korespondencji / Address for correspondence

Ardiana Murtezani

*University Clinical Center of Kosovo, rr. Spitalit pn. 10000 Prishtina
Republic of Kosovo, e-mail: ardianaa@yahoo.com*

*Otrzymano / Received 10.12.2014 r.
Zaakceptowano / Accepted 03.02.2015 r.*