Ortopedia *Traumatologia* **Rehabilitacja**
© MEDSPORTPRESS, 2006; 2(6); Vol. 8, 160-168

Zaangażowanie Autorów
A – Przygotowanie projektu badawczego
B – Zbieranie danych
C – Analiza statystyczna
D – Interpretacja danych
E – Przygotowanie manuskryptu
F – Opracowanie piśmiennictwa
G – Pozyskanie funduszy

Author's Contribution
A – Study Design
B – Data Collection
C – Statistical Analysis
D – Data Interpretation
E – Manuscript Preparation
F – Literature Search
G – Funds Collection

Marc Garcia-Elias
Hand and Upper Extremity Surgery, Institut Kaplan, Barcelona (Spain)

Treatment of scapho-lunate instability

Key words: *scapho-lunate instability, staging, treatment*

SUMMARY

Scapho-lunate dissociation is one of the most frequent reasons of carpal instability. Diagnosis is mostly based on a careful physical examination where stability of the SL joint is specifically checked through different clinical maneuvers, followed by static and dynamic radiographic examination of the wrist in a variety of positions and loading conditions aiming at demonstrating the presence of a gap between the two dissociated bones. When in doubt, arthroscopy is used. In the treatment five factors are to be considered: integrity of the dorsal SL ligament, its healing potential, status of other scaphoid stabilizers, reducibility of malaligment and cartilage status. The staging classification of SLD is also presented. On this basis the possible treatment techniques both recent and past are described, including various methods of soft tissue repair and reconstruction procedures and bony stabilization.

Liczba słów/Word count: 4199 **Tabele/Tables:** 1 **Ryciny/Figures:** 5 **Piśmiennictwo/References:** 20

Adres do korespondencji / Address for correspondence
Marc Garcia-Elias, M.D., Ph.D.
Institut Kaplan, Passeig de la Bonanova, 9, 2on 2a, 08022 Barcelona (Spain)
Phone: (+34) 934 178 484 Fax: (+34) 932 110 402, e-mail address: garciaelias@infonegocio.com

Otrzymano / Received *01.02.2006 r.*
Zaakceptowano / Accepted *14.04.2006 r.*

Carpal instability is defined as the inability of the wrist to maintain normal carpal alignment under physiologic loads throughout its range of motion [1]. Consequently, the concept of wrist instability implies both the presence of an abnormal transfer of loads (dyskinetics) and the existence of abnormal motion (dyskinematics). Based on this definition, carpal instability may result from a wide spectrum of injuries or diseases. Congenital anomalies such as Madelung's deformity, scaphoid hypoplasia, or carpal synostosis may create carpal instability. Similarly, infections, inflammatory arthritis, or any other process modifying the shape of the carpal bones may also alter the balance between carpal bones and result in instability. This article will cover only the treatment of the carpal instability secondary to traumatic disruption of the scapholunate ligaments, certainly one of the most frequent conditions in wrist pathology.

SCAPHOLUNATE DISSOCIATION

The term scapholunate dissociation (SLD) has long been utilized to describe the symptomatic dysfunction that results from rupture of the mechanical linkage between the scaphoid and lunate, with or without carpal malalignment [2,3,4]. Most SLD's are the result of an indirect mechanism of injury, usually consisting of a violent hyperextension of the wrist, associated with some ulnar deviation and radiocarpal/midcarpal supination. The most common presentation comes after a fall from a height or a motorcycle accident. Often, the term Rotary Subluxation of the Scaphoid (RSS) has been used as a synonym of SLD [5]. This is not always appropriate. RSS should be used to describe only those cases in an advanced stage of the injury, in which the ligaments attached to both ends of the scaphoid have failed and the bone has collapsed into flexion and pronation. In less advanced cases, in which only the proximal ligaments are disrupted, the scaphoid may remain normally attached to the distal row preventing a rotatory collapse of the bone. In between the two extremes, there is a broad spectrum of pathology that may or may not exhibit carpal malalignment.

The symptoms of SLD depend on the magnitude and extent of the associated injuries, as well as on the time elapsed since the accident. Weakness of grasp, and point tenderness over the dorsal aspect of the SL interval are the most frequent findings. Pain is common and may be aggravated by heavy use, sometimes coinciding with a snapping or clicking sensation with movement. Diagnosis is mostly based on a careful physical examination where stability of the SL joint is specifically checked through different clinical maneuvers, followed by a thorough static and dynamic radiographic examination of the wrist in a variety of positions and loading conditions aiming at demonstrating the presence of a gap between the two dissociated bones. Arthroscopy, when in doubt, has become the gold standard in the diagnosis of the condition [4,6].

Treatment

When deciding a treatment for a wrist with a SLD, aside from the patient's age, health status, and professional and/or vocational demands, five factors are to be considered [7]:

1. Integrity of the dorsal SL ligament: Partial SL ligament tears usually affect only the palmar SL ligament and the proximal fibrocartilaginous membrane. The dorsal SL ligament is much stronger and may have resisted the traumatic sprain without yielding.
2. Healing potential of the disrupted ligaments: If the two ends of the disrupted dorsal SL ligament are retracted and/or necrotic a poor healing potential is likely. By contrast, if there is an avulsion type of rupture where the ligament is still intact, the injury may heal if it is properly reattached.
3. Status of the secondary scaphoid stabilizers: When all SL ligaments are ruptured, the distal and palmar to the distal carpal row may still hold the scaphoid in a relatively normal alignment. It is important to evaluate whether this second line of defence is efficient or not. Usually, when these secondary constraints have failed a RSS appears, with the typical „rign” sign on the PA views, and an abnormally increased radioscaphoid angle on the lateral X-rays.
4. Reducibility of carpal malalignment: Reducibility, understood as the difficulty of achieving normal alignment due to fibrosis, is an important parameter to consider. If during surgery the scaphoid and lunate bones are brought together with minimal force the case is considered reducible. By contrast, if reduction can only be obtained by applying substantial force by means of inserted K-wires, used as „joy-sticks”, the case is to be considered irreducible. In general, no irreducible malalignment is likely to be maintained reduced by a soft-tissue reconstruction.
5. Status of cartilage. If there is a cartilage defect or joint degeneration in association to SLD the treatment can not be the same as if the cartilage is acceptably normal. Particularly prone to develop chondral degeneration are the proximo-dorsal aspects of the scaphoid and capitate bones.

Based on these five prognostic factors, every case of SLD can be classified into one of the following six

stages of the severity and/or chronicity, from mild (Stage 1) to severe (Stage 6) (Table 1).

SLD Stage 1 (Partial SL ligament injury): When the SL ligamentous complex is only partially ruptured, the wrist alignment is not altered. There may be pain, however, due to increased shear stress in the joint. This stage is often diagnosed by arthroscopy. No abnormal SL gap appears between the two bones not even under load. If the injury has been early diagnosed, percutaneous K-wire fixation is recommended. If the injury is chronic, the K-wire fixation is to be supplemented by a dorsal capsulodesis [8]. In all cases surgery is to be followed by a program of reeducation of the flexor carpi radialis muscle, the only potential dynamic stabilizer of the scaphoid [4].

SLD Stage 2 (Complete SL ligament injury, repairable): Even if there is complete disruption of all SL ligaments complex, if the distal-palmar secondary constraints, namely the scapho-trapezial-trapezoidal (STT) and scapho-capitate (SC), are intact, the carpal bones may appear relatively normally aligned. In such circumstances, a patient is considered to be in stage 2 when the dorsal SL ligament is still repairable, with good healing potential. In those, excellent recovery can be expected if the ligament is properly repaired or reattached with transosseous or anchor sutures in the early stage [9].

Stage 3 (Complete SL ligament injury, non-repairable, normally aligned scaphoid): Stage 3 is characterized by a complete rupture of the SL ligaments, the dorsal being non repairable, or with poor healing capability. Carpal alignment still is normal the scaphoid being held by the STT and SC ligaments, as well as by the most proximal fibres of the dorsal intercarpal ligament, the so-called dorsal scaphoid-triquetral (STq) ligament. In these circumstances, a bone-ligament-bone graft replacing the dorsal SL ligament could be indicated [10,11].

Stage 4 (Complete SL ligament injury, non-repairable, reducible rotary subluxation of the scaphoid): When there is a complete SL ligament injury, plus insufficiency of the distal scaphoid stabilizers (STT and SC ligaments), the scaphoid appears subluxed into flexion and pronation (RS angle >45°) while the lunate tends to appear abnormally ulnarly translated and extended, the so-called „dorsal intercalated segment instability" (DISI). For a DISI to appear, however, aside from complete detachment of the dorsal STq ligament off the distal margin of the lunate, there is a need for some sort of stretching or rupture of the long and short palmar radiolunate ligaments. To be included in this group the malalignment needs to be easily reducible, and no cartilage damage is to be present. This stage is the ideal indication for tendon stabilization as described below [7,12,13].

Stage 5 (Complete SL ligament injury with irreducible malalignment, but normal cartilage): Chronic malalignment secondary to rupture of the different SL stabilizers tends to become fixed, making difficult its reduction. Yet, some of these chronic cases exhibit no cartilage degeneration. No soft-tissue procedure can be succesful in a stage 5 unless the fibrosis that causes the irreducibility is excised, and even with this results tend to be unpredictable. This is the reason why most authors prefer a partial fusion than attempting a ligament reconstruction that most likely will

Tab. 1. Staging of scapholunate dissociations [7] (see text)

SLD Stage	1	2	3	4	5	6
Is there a partial rupture with a normal dorsal SL ligament?	Yes	No	No	No	No	No
If ruptured, can the dorsal SL ligament be repaired?	Yes	Yes	No	No	No	No
Is the scaphoid normally aligned? (normal ≤ 45º)	Yes	Yes	Yes	No	No	No
Is the carpal malalignment easily reducible?	Yes	Yes	Yes	Yes	No	No
Are the cartilages at both RC and MC joints normal?	Yes	Yes	Yes	Yes	Yes	No

fail. Different partial fusions can be utilized to maintain the scaphoid properly aligned relative to the radius. The most commonly used are the STT and SC arthrodesis [14,15].

Stage 6 (Complete SL ligament injury with irreducible malalignment and cartilage degeneration): Chronic instability of the scaphoid tend to develop cartilage degeneration following a specific pattern called „Scapho-Lunate Advanced Collapse" (SLAC). Treatment in such cases aims to relief pain with the minimum functional loss. This is usually achieved by a proximal row carpectomy or a scaphoidectomy plus midcarpal („four corner" fusion) [5].

Surgical techniques utilized in SLD

Treatment of SLD is to be taylor-made to the requirements of each individual case, based on the staging system described above. What follows is a description of the most commonly utilized surgical operations which can be used. Salvage procedures for the degenerative arthritis resulting from an unsolved SLD (stage 6) will not be discussed.

Percutaneous K-wire fixation of the SL joint. Patients with an acute SLD stage 1 may obtain excellent results by pinning the reduced joint with two or three percutaneous K-wires (Fig. 1). Fluoroscopy, and eventually arthroscopy, may help obtaining correct alignment of the scaphoid and the lunate [4,6]. Reduction

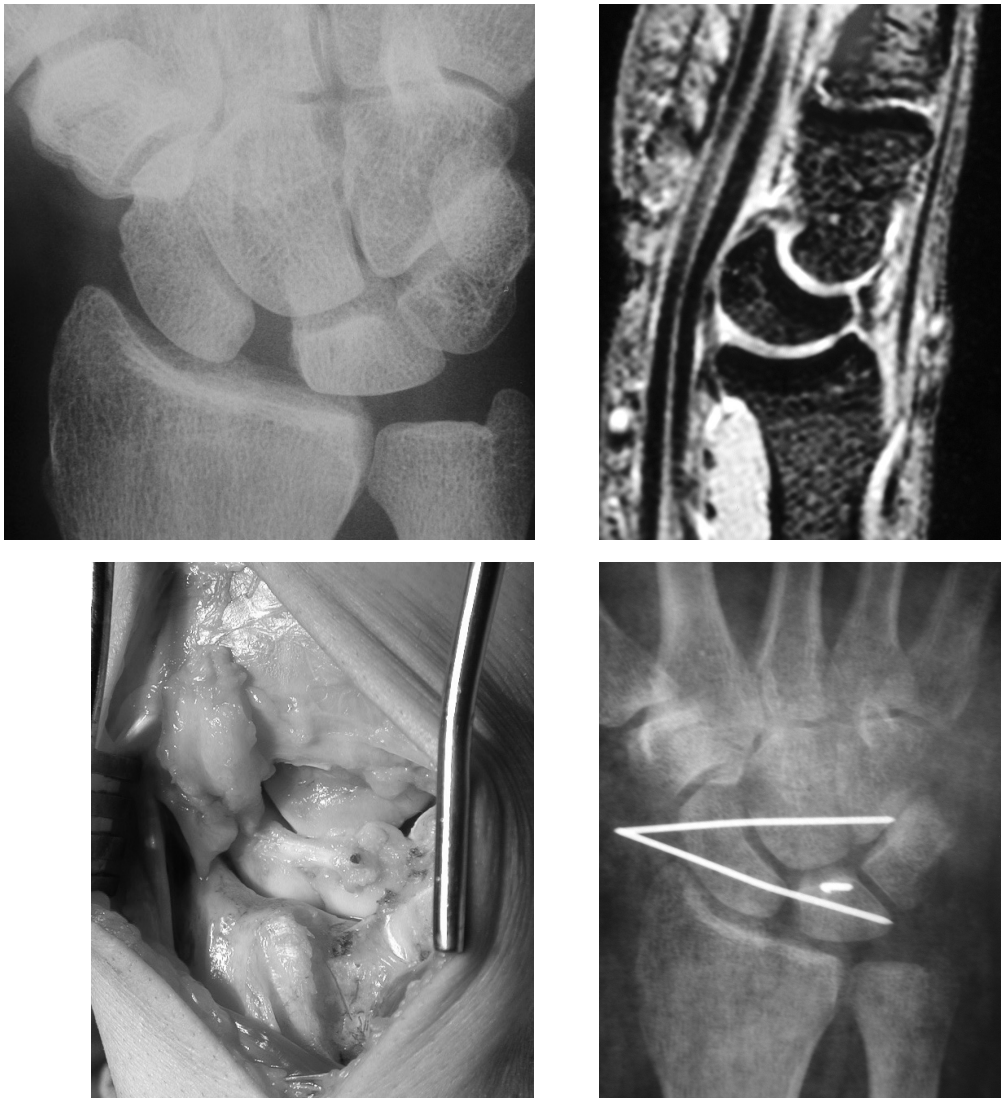

Fig. 1. Example of SL ligament reconstruction in a 42 y. o. patient who sustained a hyperextension injury to his right wrist. (A) Plain X-rays demonstrate a diastasis of the SL joint, indicating complete ligament disruption. (B) Sagittal MRI shows abnormal extension of the lunate and a small bone fragment avulsed of its dorsal pole. (C) The dorsal SL ligament, which had been detached off the lunate, has been reinserted using a small Kirschner wire. (D) Disposition of the three stabilizing wires, maintained for a period of 10 weeks. Function at one year was good, with only minimal reduction of the extremes of motion, and 24% decreased grip strength

of the displaced bones can be facilitated by placing two K-wires percutaneously into the dorsal aspects of both scaphoid and lunate to facilitate reduction. If there is no soft tissue interposition, by pulling the scaphoid wire proximally and ulnarly while the lunate wire is directed distally and radially, the joint becomes reduced. To ensure maximal stability, some authors recommend transfixing the SC joint with another wire. The wrist is immobilized in a below elbow cast for 6 weeks and in a removable splint for an additional 4 weeks. The wires are removed at 8 to 10 weeks. Physical therapy for range of motion exercises of the fingers is initiated immediately. Gentle radiocarpal motion exercises are initiated at six weeks and grip strengthening is begun at three months. Strenuous activities are discouraged for the first 6 months.

Open Reduction, Internal Fixation, and Repair of the dorsal SL ligament. Direct ligament repair is only recommended when the dorsal SL ligament has good healing potential, when the STT and SC ligaments are still intact and if there is no cartilage damage in the wrist. In other words, this approach is only recommended in stage 2.4,9. A dorsal approach to the wrist capsule between the third and fourth extensor compartments is recommended. Frequently, when operating early on a torn dorsal SL ligament, there is sufficient ligamentous tissue to permit a reasonable repair. If the ligament is not ruptured but avulsed, the repair is more effective and consists of reattaching the avulsed ligament to the freshened dorsal edge of the scaphoid or lunate by using transosseous sutures or by using tag suture anchors. The repair is to be protected by transfixing both the SL and SC joints with K-wires. In many instances this is supplemented with a dorsal capsulodesis as described below. The wires are maintained for a period of 8 to 10 weeks with protection in a removable splint for an additional 4 weeks.

Dorsal Radioscaphoid Capsulodesis. Popularized by Gerald Blatt [8], this method of treatment is one of the most commonly utilized techniques in the treatment of carpal instability [16,17]. It consists of tightening the dorsal capsule between the radius and scaphoid to prevent excessive scaphoid rotation into flexion. It can be used as an isolated gesture in a stage 1 SLD, or to protect a direct repair of the dorsal SL ligament in stage 2. The capsulodesis is created by raising a 1-cm-wide dorsal capsular flap, leaving its proximal edge attached to the dorsal rim of the radius. Once the scaphoid is reduced by manipulation and maintained with a single K-wire passed obliquely from the distal pole of the scaphoid into the capitate, the capsular flap is tightly inserted into a notch created on the dorsum of the scaphoid at a point distal to the axis of rotation of the scaphoid. Anchor sutures are ideal for this matter. A thumb spica cast is applied for 2 months, after which active range-of--motion exercises are begun. The K-wire may be left in place for an additional month. Intercarpal motion usually begins 3 months postoperatively.

Bone-ligament-bone reconstruction of the dorsal SL ligament. Based on the proven success of bone-ligament-bone grafts in knee reconstructions, some authors have reported acceptable results in stage 3 SLD by transferring to the dorsum of the SL joint a bone--ligament-bone autograft harvested from the region, most often the dorsal third metacarpal-capitate ligament or the dorsal hamate-capitate ligament [10,11]. The surgical approach is identical as for a direct repair. Once the two bones are reduced and transfixed by K-wires, a deep trough is carved at both sides where the bone-ligament-bone graft is buried and fixed with either mini screws or small wires. Several problems may arise, however, most in the form of non-union of the graft. Owing to the relatively high index of failures, this technique is not recommended in stage 4 SLD.

Tendon reconstruction of the palmar SC ligament and dorsal SL ligament. The use of tendon grafts to reconstruct the SL ligaments has evolved considerably in the last decades. The initial idea was to pass a strip of tendon through holes in the scaphoid and lunate in order to provide immediate stability by using the tendon graft as a loop around the joint [18]. Unfortunately, the method was based on creating large drill holes in vascular compromised areas, interfering with blood supply, thus resulting in fractures and/or joint degeneration. In the 90's, Giorgio Brunelli advocated the use of a strip of the flexor carpi radialis (FCR) tendon which is left attached distally and passed through a drill hole made across the distal scaphoid [12]. The split tendon that emerges off the scaphoid hole is sutured to the remnants of the dorsal SL ligament before being pulled taut proximally and anchored to the dorsal-ulnar corner of the distal radius by transosseous sutures. This method, which is only recommended in stage 4 SLD, has been subsequently modified by Van den Abbeele et al, and later by Garcia-Elias et al, as follows (Fig. 2,3,4) [7,13].

Once the dorsum of the SL joint is exposed, a drill hole entering the scaphoid at the point of insertion of the dorsal SL ligament is made. The tunnel is to follow the longitudinal axis of scaphoid, aiming at the palmar tuberosity where a small transverse incision is made and used to localize the FCR tendon. Using two or more proximal transverse incisions a distally based 8 cm strip of FCR tendon is obtained and passed through the scaphoid tunnel using a wire loop or

a tendon passer. Back to the dorsal incision, a 3 mm transverse trough or channel over the dorsum of the lunate is then made with a rongeur. This trough needs to be deep enough as to uncover cancellous bone, the only tissue allowing growing of tendon fibers from the graft. In order to obtain intimate contact between the tendon strip and the lunate cancellous bone, an anchor suture is placed into in the floor of the trough.

The dorsal radiotriquetral ligament is then localized. A slit is created in its distal end, just proximal to its triquetral attachment, through which the tendon strip is passed. The radiotriquetral ligament will be used as a pulley to tension the ligament strip.

Before tightening the tendon, the scaphoid, lunate and capitate are reduced and stabilized with several K-wires across the SL and SC joints. The tendon graft is then tightened up, sutured onto itself, and the anchor suture in the lunate is used to bring the tendon strip in close contact with the lunate cancellous bone.

A short arm thumb spica cast is placed, changed at 10 days for stitch removal, and maintained for a total 6 weeks when wires are taken out. A protective removable splint allowing supervised rehabilitation is used for an additional 4 weeks. As said above for other surgical techniques, contact sports are to be avoided during 6 months after surgery.

Scaphoid-trapezium-trapezoid arthrodesis. Until recently, STT arthrodesis has been one of the most popular methods of treatment for the chronic SLD, stage [5,14,15]. The goal of the procedure is to restore the radioscaphoid congruency by fusing the bone to the distal row in such a way that prevents its proximal pole to escape off the scaphoid fossa. When planning an STT fusion, it is important that the external dimensions of the fused block are the same as the external dimensions of the bones in the normal wrist. To fulfill this, once the articular cartilage and subchondral bone are removed, the gap remaining be-

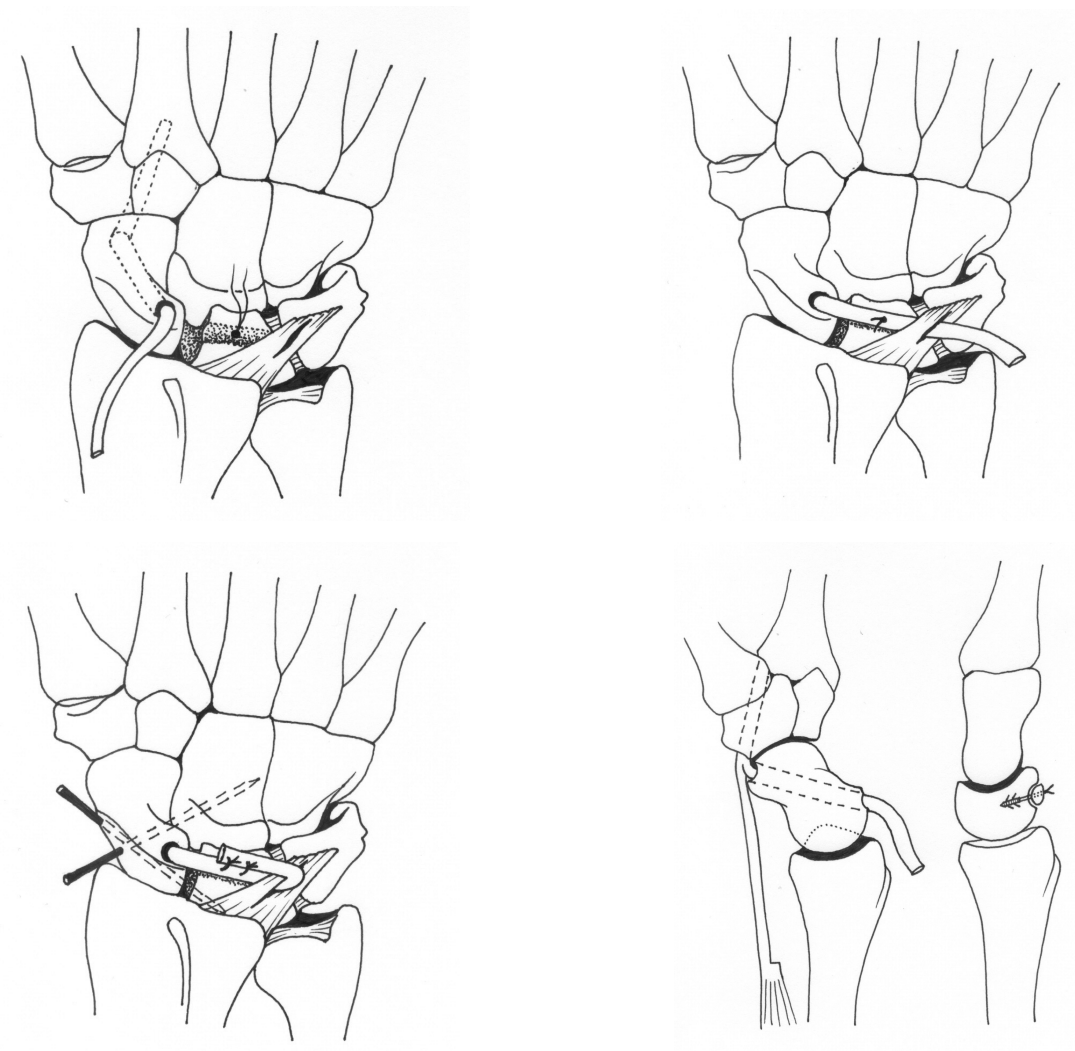

Fig. 2. Schematic representation of the 3LT procedure, as described by Garcia-Elias et al7, to treat SLD stage 4

tween the bones must be filled with bone graft, and the bones must not be pressed together while transfixing the fusion site with K-wires. The wrist is immobilized for 3 weeks in a long arm cast, including the MP joints of the thumb, index and middle fingers, followed by 3 more weeks in a short arm cast.

As experience with STT fusion has accumulated, however, complications and adverse long-term effects have been reported [19]. Painful radioscaphoid impingement is a frequent problem owing to the fact that in radial deviation the distally fused scaphoid can no longer rotate into flexion, resulting in an increased pressure on the scaphoid fossa. To prevent

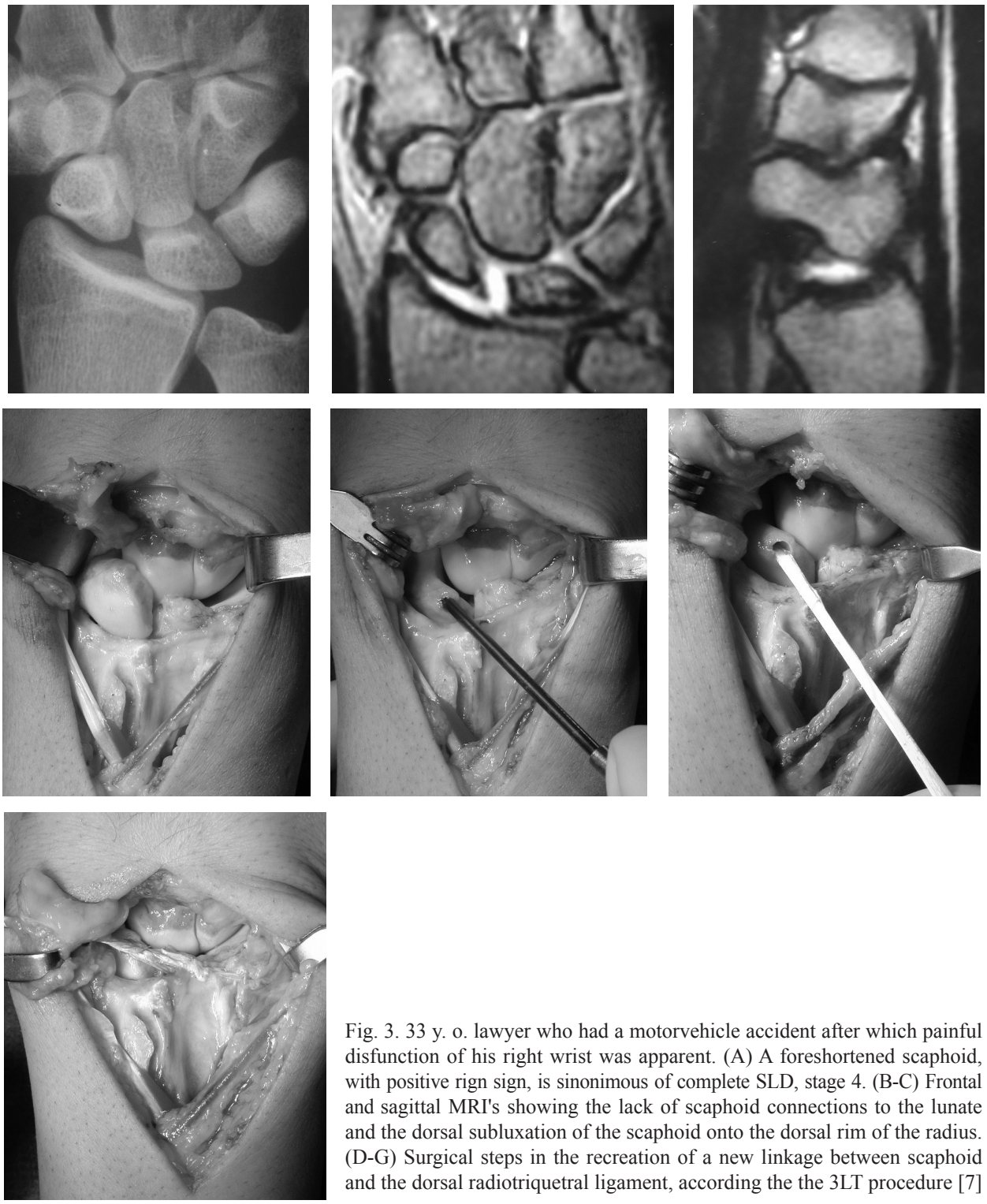

Fig. 3. 33 y. o. lawyer who had a motorvehicle accident after which painful disfunction of his right wrist was apparent. (A) A foreshortened scaphoid, with positive rign sign, is sinonimous of complete SLD, stage 4. (B-C) Frontal and sagittal MRI's showing the lack of scaphoid connections to the lunate and the dorsal subluxation of the scaphoid onto the dorsal rim of the radius. (D-G) Surgical steps in the recreation of a new linkage between scaphoid and the dorsal radiotriquetral ligament, according the the 3LT procedure [7]

Fig. 4. (A) Preoperative X-rays of the wrist of a patients having a SLD with complete ligament disruption (early stage 4). (B) X-rays obtained 3 years after undergoing a 3LT procedure. The wrist remains stable and painfree (Reprinted from Garcia-Elias et al. J Hand Surg 2006; 31A:125-134)

this problem, a dorsolateral styloidectomy is recommended as a routine part of the STT fusion.

Scaphoid-Lunate-Capitate (SLC) Arthrodesis. One of major criticisms of STT arthrodesis is the fact that does not control the frequently misaligned lunate. This can be alternatively addressed by fusing the SLC joint. It is indicated in a patient with severe fixed instability without degenerative changes on the proximal pole of the scaphoid and apposing articular surface of the radius (SLD stage 5). The consequence of this is approximately a 50 percent reduction of wrist motion. Unfortunately, the percentage of patients claiming residual radioscaphoid impingement pain after the procedure is not low, and seldom can this complication be solved by radial styloidectomy [4].

Radio-scapho-lunate (RSL) fusion plus distal scaphoidectomy. Recently a new biomechanical concept has been introduced suggesting new ways of approaching the SLD stage 5.20. As it is well known, most activities of daily living involve motion along the so-called „dart-throwing" plane, which is from extension-radial deviation to flexion-ulnar deviation (Fig. 5). Such a motion occurs mostly at the midcarpal joint. Consequently, if the fixed malalignment of the sca-

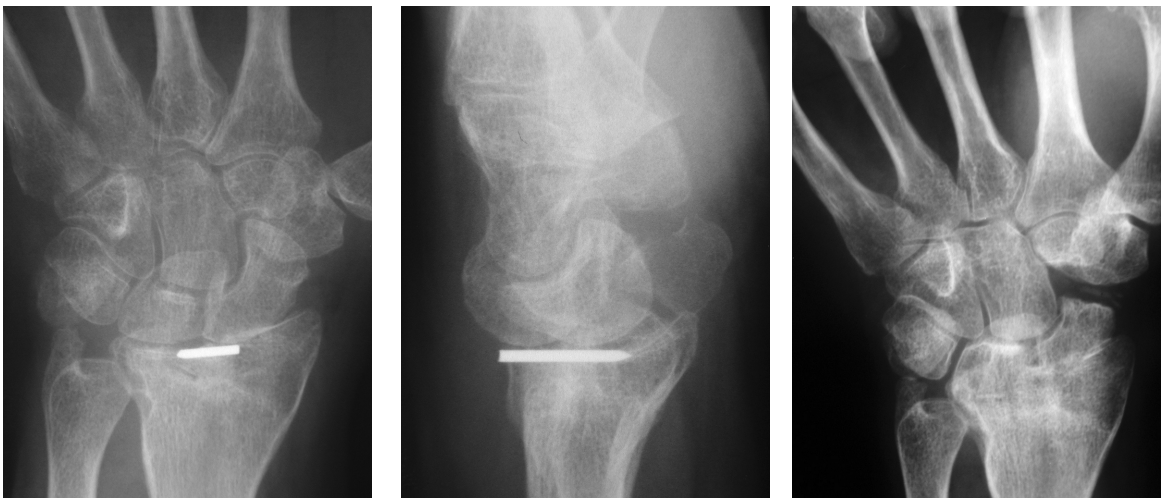

Fig. 5. (A-B) X-ray appearance of the wrist of a 37 y. o. man who had sustained an intraarticular distal radial fractured treated by external fixation and percutaneous K-wires. Unfortunately, a badly malaligned SL dissociation was missed at presentation causing painful dysfunction with substantial loss of motion. (C) 4 years after a RSL fusion and distal scaphoidectomy, the patient has painfree midcarpal function with which he can cope effectively with most working and leasure activities

phoid and lunate needs to be reduced and fixed somewhere, it is reasonable to fuse them to the radius rather than spoiling the midcarpal joint. If aside from the dissociation, there are degenerative changes at the radioscaphoid joint (stage 6) being the midcarpal articulation normal, an arthrodesis of the RSL joint is even a better choice. When fusing the RSL joint, however, the STT joint may become symptomatic and degenerate with time as the consequence of the inability of the scaphoid to flex during wrist flexion and/or radial deviation creating a local impingement. To avoid such a complication, and to increase the resultant motion, excision of the distal third of the scaphoid is recommended. With this modified technique, the midcarpal „ball-and-socket" articulation is freed from its lateral constraint and allows more than 50% of the overall wrist motion. The early results published so far are very encouraging.

REFERENCES

1. Anatomy and Biomechanics Committee of the IFSSH: Position Statement: Definition of Carpal Instability. J Hand Surg 1999; 24A: 866-867.
2. Linscheid RL, Dobyns JH, Beabout JW, Bryan RS. Traumatic instability of the wrist: Diagnosis, classification, and pathomechanics. J Bone Joint Surg 1972; 54A: 1612-1632.
3. Walsh JJ, Berger RA, Cooney WP. Current status of scapholunate interosseous ligament injuries. J Am Acad Orthop Surg 2002; 10: 32-42.
4. Garcia-Elias M, Geissler WB. Carpal Instabilities. In: Green DP, Hotchkiss RN, Pederson WC, Wolfe SW (eds.): Green's Operative Hand Surgery. 5th ed. Philadelphia: Elsevier-Churchill Livingstone, 2005: 535-604.
5. Watson HK, Ballet FL. The SLAC wrist: Scapholunate advanced collapse pattern of degenerative arthritis. J Hand Surg 1984; 9A: 358-365.
6. Geissler WB, Freeland AE, Savoie FH, McIntyre LW, Whipple TL. Intracarpal soft-tissue lesions associated with an intra-articular fracture of the distal end of the radius. J Bone Joint Surg 1996; 78A: 357-365.
7. Garcia-Elias M, Lluch AL, Stanley JK. Three-ligament tenodesis for the treatment of scapholunate dissociation: Indications and surgical technique. J Hand Surg 2006; 31A: 125-134.
8. Blatt G. Capsulodesis in reconstructive hand surgery. Dorsal capsulodesis for the unstable scaphoid and volar capsulodesis following excision of the distal ulna. Hand Clin 1987; 3: 81-102.
9. Lavernia CJ, Cohen MS, Taleisnik J. Treatment of scapholunate dissociation by ligamentous repair and capsulodesis. J Hand Surg 1992; 17A: 354-359.
10. Weiss APC. Scapholunate ligament reconstruction using a bone-retinaculum-bone autograft. J Hand Surg 1998; 23A: 205-215.
11. Harvey EJ, Hanel DP. Bone-ligament-bone reconstruction for scapholunate disruption. Tech Hand Upper Extr Surg 2002; 6: 2-5.
12. Brunelli GA, Brunelli GR. A new technique to correct carpal instability with scaphoid rotary subluxation: A preliminary report. J Hand Surg 1995; 20A: S82-S85.
13. Van Den Abbeele KLS, Loh YC, Stanley JK, Trail IA. Early results of a modified Brunelli procedure for scapholunate instability. J Hand Surg 1998; 23B: 258-261.
14. Watson HK, Ryu J, Akelman E. Limited triscaphoid intercarpal arthrodesis for rotatory subluxation of the scaphoid. J Bone Joint Surg 1986; 68A: 345-349.
15. Watson HK, Weinzweig J, Guidera PM, Zeppieri J, Ashmead D. One thousand intercarpal arthrodeses. J Hand Surg 1999; 24B: 307-315.
16. Szabo RM, Slater RR, Palumbo CF, Gerlach T. Dorsal intercarpal ligament capsulodesis for chronic, static scapholunate dissociation: Clinical results. J Hand Surg 2002; 27: 978-984.
17. Uhl RL, Williamson SC, Bowman MW, Sotereanos DG, Osterman AL. Dorsal capsulodesis using anchors. Am J Orthop 1997; 26: 547-548.
18. Palmer AK, Dobyns JH, Linscheid RL. Management of post-traumatic instability of the wrist secondary to ligament rupture. J Hand Surg 1978; 3: 507-532.
19. Kleinman WB, Carroll C. Scapho-trapezio-trapezoid arthrodesis for treatment of chronic static and dynamic scapho-lunate instability: A 10-year perspective on pitfalls and complications. J Hand Surg 1990; 15A: 408-414.
20. Garcia-Elias M, Lluch A, Ferreres A, Papini-Zorli I, Rahimtoola ZO. Treatment of radiocarpal degenerative osteoarthritis by radioscapholunate arthrodesis and distal scaphoidectomy. J Hand Surg 2005; 30A: 8-15.