Ortopedia *Traumatologia* **Rehabilitacja**
© MEDSPORTPRESS, 2008; 3(6); Vol. 10, 286-291

Simultaneous Bilateral Quadriceps Tendon Rupture in a Patient on Chronic Haemodialysis (Short-term Results of Treatment with Transpatellar Sutures Augmented with a Quadriceps Tendon Flap)

Cemil Kayali[(A,B,C,D,E,F)], **Haluk Agus**[(A,B,C,D,E,F)], **Ali Turgut**[(A,B,C,D,E,F)], **Can Taskiran**[(A,B,C,D,E,F)]

Tepecik Education and Research Hospital, Second Orthopaedic and Traumatology Department, Izmir, Turkey

SUMMARY

Quadriceps tendon ruptures are rare orthopaedic injuries. Although they are generally seen after the age of 50, they may occur in younger patients with certain underlying conditions, including chronic haemodialysis. Several repair techniques have been proposed but the choice of the best method is still a matter of controversy. This paper presents the case of a renal failure patient with 10 years' history of haemodialysis treatment suffering from bilateral quadriceps tendon rupture. The treatment was with transpatellar sutures augmented with a reverse quadriceps tendon flap. His short-term clinical and radiological results are satisfactory.

Key words: Quadriceps Tendon, Rupture, Repair, Chronic Haemodialysis

BACKGROUND

Ruptures of the quadriceps tendon are not common injuries and bilateral tendon ruptures are extremely rare [1,2]. The majority of cases have been reported in patients over 50 years of age. Approximately 70% of the patients suffering from quadriceps tendon rupture have predisposing medical factors such as prolonged systemic steroid use [3], chronic renal failure resulting in hyperparathyroidism [4,5], diabetes mellitus [6], osteogenesis imperfecta [7], systemic autoimmune diseases like gout, rheumatoid arthritis, pseudogout [8], systemic lupus erythematosus [9], vasculitis, obesity, and other metabolic diseases [10]. Amyloidosis and use of anabolic steroids and fluoroquinolones have also been implicated as factors in tendon rupture [11]. Isolated cases have also been described in healthy individuals [12,13]. Generally these patients give the same history of a rupture simultaneous with or secondary to a minor trauma.

This case report presents the short-term treatment results of a bilateral quadriceps tendon rupture in a patient treated by transosseous sutures with augmentation according to the Scuderi technique [14].

CASE REPORT

A 40-year-old man (weight 67 kg, height 165 cm) with chronic renal failure was admitted to our centre. His presenting complaint was inability to walk. He had fallen down from a height of 80 cm onto his feet with both knees extended, following which he was unable to get up on both legs. He felt a sharp snap and pain in his knees and afterwards he was unable to walk on his own. On inspection both knees were mildly swollen. Gaps were palpated bilaterally just proximal to the patella. The gap areas were painful. He was able to flex his knees and but not to extend them.

His laboratory findings were as follows; BUN: 160 mg/dl, Creatinine: 10.5 mg/dl, Uric acid: 6.7 mg/dl, ESR: 12 mm/h, Glucose: 90 mg/dl, Sodium: 138 mmol/l, Potassium: 5.4 mmol/l, Calcium: 10.9 mg/dl, Hb: 13.2 g/dl, Hct: 37.4%, WBC: 5470/microliter, Platelets: 171000/mm^3, Anti-HCV: positive, and parathyroid hormone (PTH): 372 pg/ml (normal range 10-65).

Plain radiographs of both knees showed evidence of patella baja. MRI of both knees was performed to confirm the diagnosis and to evaluate the soft tissues around the knees. Sagittal images displayed evidence of bilateral quadriceps tendon rupture at the osseotendinous junction of the patella (Fig. 1, 2). Small bony fragments that originated from the superior pole of the patella were seen.

He was operated within 72 hours of admission to hospital. The operation was carried out under general anesthesia. An approximately 10 cm longitidunal midline incision was performed on the left knee starting from the middle portion of the patella to the distal part of thigh after inflation of a pneumatic tourniquet. A thorough wash-out of the knee joint and debridement of the tendon ends were carried out.

Fig. 1. Sagittal MRI image of the left knee. The rupture can be clearly seen at the osseo-tendinous junction

Fig. 2. Sagittal MRI image of the right knee

Four holes were prepared by drilling the patella using a 2.5 mm drill bit. No. 5 non-absorbable sutures (tycron) were passed through the holes in the patella (Fig. 3). These sutures were then passed in the quadriceps tendon in a criss-cross manner and tied with each other with the knee in full extension. A reverse V-shaped tendinous quadriceps flap was prepared. It was rotated 180o distally and sutured onto the patella using absorbable No. 2/0 sutures (Fig. 4). A long cylindrical leg cast was applied after wound closure. The same procedure was used to operate on the right knee.

The patient was encouraged to begin weight-bearing with crutches as tolerated after removal of suction drains. Isometric exercises for the quadriceps were introduced during this stage. The cylindrical casts were removed at 6 weeks postoperatively. A long leg brace allowing angle control was recommended bilaterally for 8 weeks. Active and passive rehabilitation was encouraged while the patient was

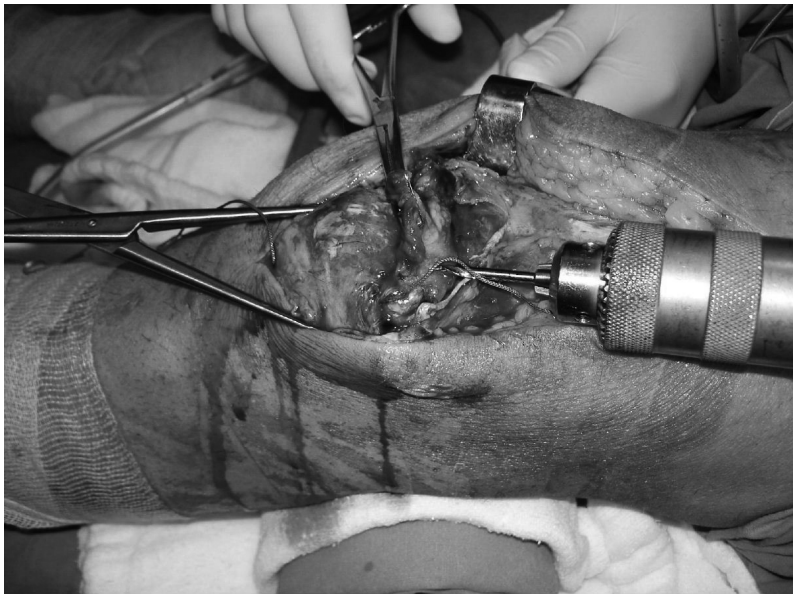

Fig. 3. Drilling the patella and passing a non-absorbable No. 5 suture though the holes

Fig. 4. Augmentation of the repair site with a reverse tendon flap onto the patella

Fig. 5. Full extension while standing

using the brace. The last follow-up was done at 4 months postoperatively. The patient was able to fully extend both knees without any support and flex to about 140° (Fig. 5, 6). He is asymptomatic now and he can perform all recreational activities that he engaged in before the injury.

DISCUSSION

A spontaneous bilateral rupture of the quadriceps tendon is a rare injury [2]. Most cases have been related to underlying medical conditions such as chronic haemodialysis or systemic inflammatory diseases [15]. Mechanical and concomitant systemic factors have been implicated in the pathogenesis of major tendon ruptures, with diminished blood supply appearing to be the most important factor for these injuries [16].

Two pathophysiologic mechanisms have been implicated as factors underlying spontaneous tendon rupture in chronic renal failure patients with elevated PTH levels. Some reports have pointed to a relation between the duration of haemodialysis and the inci-

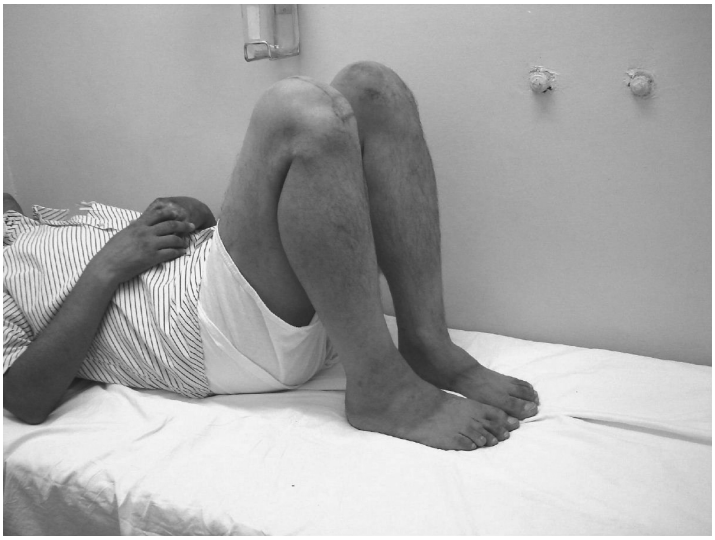

Fig. 6. 140° flexion in both knees

dence of tendon ruptures [17]. These reports suggested that tendinous weakness in these cases resulted from malnutrition, 2-amyloidosis or the accumulation of uraemic toxins [18]. On the other hand, secondary hyperparathyroidism is thought to be a risk factor for tendon rupture, the rationale starting with retention of phosphorus due to decreased glomerular filtration rate that leads to hypocalcaemia, which stimulates PTH [15,19,20].

In a study of 24 renal failure patients, Shah reported that the duration of haemodialysis was related to quadriceps tendon rupture. However he could find no relation between demographic data, hyperparathyroidism and tendon rupture [17]. Our patient had mildly elevated PTH but had been receiving haemodialysis for about 10 years. Therefore in our case the duration of chronic haemodialysis seems a more probable predisposing factor than hyperparathyroidism.

A number of operative techniques are available for quadriceps tendon rupture apart from transpatellar repair plus reverse quadriceps tendon flap, such as the use of Dacron vascular grafts, polydioxane cord, carbon fibre, synthetic prosthetic ligaments, and suture anchors [21-24]. Which of these is the most suitable is still a matter of controversy. Ravalin et al. reported that augmentation of tendon repair decreases the incidence of gap formation and clinical failure [25]. In the meta-analysis reported by Neubauer et al., transpatellar tendon repair was the most common and preferred technique in the literature (57.7%) [26]. augmentation with cerclage wiring was used in some reports [5,8]. However, the cerclage was removed because of skin irritation. Augmentation with the V-Y turndown, such as the Scuderi technique, was recommended only in chronic ruptures in which the tendon retracted proximally and could not be anatomically reduced [21].

However, in our patient, after suturing the tendon to the patella through holes, we augmented the repair site with a reverse quadriceps tendon flap as described by Scuderi [14]. Therefore we strongly encouraged our patient to carry out active and passive exercises after cast removal. Although the assessment took place early on after the operation, nearly 140° range of motion was obtained in both knees. This functional recovery appeared to be more rapid compared to other case reports [4,8].

In the literature, acute repair of the quadriceps tendon rupture is recommended by most authors. However, there are no clear recommendations regarding the duration of the period between the injury and the operation. Scuderi advocated tendon repair within the first 48-72 hours [14]. However, Rougraff et al recommended extending this period up to 7 days, and Siwek and Rao, up to 14 days [27,28]. On the other hand Ramseier et al. reported good results following surgery within 1 month since injury [29].

In our patient the surgical repair was performed within 3 days of the injury. We encouraged the patient to start weight bearing as tolerated during cast immobilisation. Active and passive rehabilitation was begun after removal of the cast. At 4 months postoperatively, the patient was free of any limitation in recreational activites and he was pleased with the clinical result.

A spontaneous bilateral quadriceps tendon rupture is an uncommon injury. Early surgical repair using transpatellar sutures and augmentation with a reverse quadriceps tendon yielded satisfactory results in our patient in the early postoperative period.

REFERENCES

1. Hardy JRW, Chimutengwende-Gordon M, Bakar I. Rupture of the quadriceps tendon. An association with a patellar spur. J Bone Joint Surg (Br) 2005; 87: 1361 - 3.
2. Heyde CE, Mahlfeld K, Stahel PF, Kayser R. Ultrasonography as a reliable diagnostic tool in old quadriceps tendon ruptures: a prospective multicentre study. Knee Surg Sports Traumatol Arthrosc 2005; 13: 564 - 8.
3. Konrath GA, Chen D, Lock T, et al. Outcomes following repair of quadriceps tendon ruptures. J Orthop Trauma 1998; 12: 273 - 9.
4. Kim YH, Shafi M, Lee YS, Kim JY, Kim WY, Han CW. Spontaneous and simultaneous rupture of both quadriceps tendons in a patient with chronic renal failure. A case studied by MRI both preoperatively and postoperatively. Knee Surg Sports Traumatol Arthrosc 2006; 14: 55 - 9.
5. Muratli HH, Celebi L, Hapa O, Bicimoglu A. Simultaneous rupture of the quadriceps tendon and contralateral patellar tendon in a patient with chronic renal failure. J Orthop Science 2005; 10: 227 - 32.
6. Zadeh KK, Singh K, Kleiner M, Jarrett MP, Luft FC. Nontraumatic bilateral rupture of patellar tendons in a diabetic dialysis patient with secondary hyperparathyroidism. Nephrol Dial Transplant 1997; 12: 1988 - 90.
7. Figueroa D, Calvo R, Vaisman A. Spontaneous and simultaneous bilateral rupture of the quadriceps tendon in a patient with osteogenesis imperfecta. Knee 2006; 13: 158 - 60.
8. Wenzl ME, Kirchner R, Seide K, Strametz S, Jürgens C. Quadriceps tendon ruptures - is there a complete functional restitution? Injury 2004 Sep; 35: 922 - 6.
9. Wener JA, Schein AJ. Simultaneous bilateral rupture of the patellar tendon and quadriceps expansions in systemic lupus erythematosus. J Bone Joint Surg (Am) 1974; 56: 823 - 4.
10. Chua SY, Chang HC. Bilateral spontaneous rupture of the quadriceps tendon as an initial presentation of alkaptonuria. Knee 2006; 13: 408 - 10.
11. Marti HP, Stoller R, Frey FJ. Fluoroquinolones as a cause of tendon disorders in patients with renal failure / renal transplants. Br J Rheumatol 1998; 37: 343 - 4.
12. Johnson AE, Rose SD. Bilateral quadriceps tendon ruptures in a healthy, active duty soldier: Case report and review of the literature. Military medicine 2006; 171: 1251 - 4.
13. Katz T, Alkalay D, Rath E, Atar D, Sukenik S. Bilateral simultaneous rupture of the quadriceps tendon in an adult amateur tennis player. J Clin Rheumatol 2006; 12: 32 - 3.
14. Scuderi C. Ruptures of the quadriceps tendon: study of twenty tendon ruptures. Am J Surg 1958; 95: 626 - 34.
15. Thaunat M, Gaudin P, Naret C, Beaufils P, Thaunat O. Role of secondary hyperparathyroidism in spontaneous rupture of the quadriceps tendon complicating chronic renal failure. Rheumatology 2006; 45: 234 - 5.
16. Kannus P, Jozsa L. Histopathological changes preceding spontaneous rupture of a tendon. A controlled study of 891 patients. J Bone Joint Surg (Am) 1991; 73: 1507 - 25.
17. Shah MK. Simultaneous bilateral quadriceps tendon rupture in renal patients. Clin Nephrol 2002; 58: 118 - 21.
18. Kurer MH, Baillod RA, Madgwick JC. Musculoskeletal manifestations of amyloidosis. A review of 83 patients on haemodialysis for at least ten years. J Bone Joint Surg (Br) 1991; 73: 271 - 6.
19. Cirincione RJ, Baker BE. Tendon ruptures with secondary hyperparathyroidism. A case report. J Bone Joint Surg (Br) 1975; 57: 852 - 3.
20. Shiota E, Tsuchiya K, Yamaoka K, Kawano O. Spontaneous major tendon ruptures in patients receiving long term hemodialysis. Clin Orthop 2002; 394: 236 - 42.
21. Bushnell B, Whitener GB, Rubright JH, Creighton RA, Logel KJ, Wood ML. The use of suture anchors to repair the ruptured quadriceps tendon. J Orthop Trauma 2007; 21: 407 - 3.
22. Farrell CM, Scuderi GR, Easley MA. Quadriceps tendon rupture. In: Scott WN, editor. Insall & Scott Surgery of the Knee. 4th ed. Philadelphia: Elsevier; 2006. p. 969 - 76.
23. Kerin C, Hopgood P, Banks A. Delayed repair of the quadriceps using the Mitek anchor system: a case report and review of the literature. Knee 2006; 13: 161 - 3.
24. Labib SA, Hage WD. A simple technique for transpatellar fixation of quadriceps tendon rupture. Orthopedics 2001; 24: 743 - 5.
25. Ravalin RV, Mazzocca AD, Grady-Benson JC, Nisse CW, Adams DJ. Biomechanical comparison of patellar tendon repairs in a cadaver model: an evaluation of gap formation at the repair site with cyclic loading. Am J Sports Med 2002; 30: 469 - 73.
26. Neubauer Y, Wagner M, Potschka T, Riedl M. Bilateral simultaneous rupture of the quadriceps tendon: a diagnostic pitfall? Report of three cases and meta – analysis of the literature. Knee Surg Sports Traum Arthros 2007; 15: 43 - 53.
27. Rougraff BT, Reeck CC, Essenmacher J. Complete quadriceps tendon ruptures. Orthopedics 1996; 19: 509 - 14.
28. Siwek CW, Rao JP. Ruptures of the extensor mechanism of the knee joint. J Bone Joint Surg (Am) 1981; 63: 932 - 7.
29. Ramseier LE, Werner CML, Heinzelmann M. Quadriceps and patellar tendon rupture. Injury 2006; 37: 516 - 9.

Liczba słów/Word count: 2327 **Tabele/Tables:** 0 **Ryciny/Figures:** 5 **Piśmiennictwo/References:** 29

Adres do korespondencji / Address for correspondence
Cemil Kayali
6445 sokak No:10 D:4 35550 Karsiyaka – Izmir / TURKEY
Telephone: + 90 232 469 69 69, Fax: + 90 232 433 07 56, e-mail: cemilkayali@yahoo.com

Otrzymano / Received *04.02.2008 r.*
Zaakceptowano / Accepted *15.05.2008 r.*