

# Draining Infected Non Union of the Distal Third of the Tibia. The Use of Invaginating Focking Over Short Distances in Older Patients

Shabir Ahmed Dhar<sup>(A,B,C,D,E,F)</sup>, Mohammed Farooq Butt<sup>(A,B,C)</sup>,  
Mohammed Ramzan Mir<sup>(B,C,E)</sup>, Altaf Ahmed Kawoosa<sup>(B,C,E)</sup>, Asif Sultan<sup>(A,B,C,D)</sup>,  
Tahir Ahmed Dar<sup>(A,B,C)</sup>

Government Hospital for Bone and Joint Surgery, Bagat, Barzullah, Srinagar, Kashmir

## SUMMARY

**Background.** The distal third of the tibia is unique in the sense that it has a minimal muscle cover and consequently the blood supply is easily compromised after a fracture in this area. Infected non union in this area provides a challenge to the orthopaedic surgeon. These difficulties are especially profound in the geriatric age group.

**Material and methods.** 12 cases with an infected non union of the distal third of the tibia were managed with acute docking over a distance of up to 2.5 cms. The age of these patients was more than 55 years.

**Results.** The average shortening at final follow up was 1.8 cms. The bone results were assessed according to the protocol laid down by the association for the study and application of the method of Ilizarov. Accordingly we had 3 excellent, 8 good and 1 fair result. The functional result was calculated as per the Ilizarov criteria [1]. On this basis we had 7 excellent, 4 good and 1 fair result.

**Conclusion.** The acute docking modality is applicable to the distal tibia in such situations even in the geriatric population with predictable results.



## BACKGROUND

Ilizarov discovered that living tissue when subjected to slow steady traction, becomes metabolically activated in both the biosynthetic and proliferative pathways, a phenomenon dependent on vascularity and functional use [1].

This method has provided new potential for the salvage of the residuals of non union, pseudoarthrosis, segmental defect, shortening, malunion, chronic osteomyelitis and soft tissue atrophy [2]. It is possible to lengthen skin and muscle flaps as well as bone defects without an additional reconstructive procedure. However, one has to balance these advantages against the frequency of complications, the duration of treatment, the number of procedures, the requirement of bone grafting, poor quality of skin and articular stiffness [3].

Infected tibial non unions in the distal third of the bone often provide difficult challenges for the orthopaedic surgeon. Deformity, poor soft tissue cover and sequestrae often complicate surgery especially in the older patients [4]. We report the results of twelve patients with an age above 55 years where we applied acute invaginating shortening in the distal third of the tibia.

## MATERIAL AND METHODS

From June 2002 to Nov 2006, 12 cases with an age above 55 years were admitted to the Government hospital for bone and joint surgery for treatment of an infected non union of the tibia. Informed consent was

obtained from all patients after explaining the procedure and its advantages and potential complications.

All 12 patients with an age range of 56-71 years participated in this prospective study. There were 8 males and 4 females. The primary cause of injury was a road traffic accident (RTA) in 8 and fall from a height in 4. In 7 cases the right side was involved and in 5 the left side was involved. The original injury was type 1 compound in 1 case, type 2 compound in 10 cases and type 3 compound in 1 case. Before the application of the peg in hole modality of treatment the number of surgical interventions averaged 3.3 per patient. These previous modalities included external fixation, previous Ilizarov frame application, interlocking nailing, bone grafting and skin grafting including free flap coverage. The duration of treatment before application of the final procedure averaged 7.9 months per patient.

## Operative method

The application of the technique necessitated a minute and detailed study of the radiographs of the involved bone taken in the anteroposterior and lateral planes (Fig. 1). The bone ends were classified as per the classification of Schwartzmann et al. [5]. Only those cases where at least one of the two main fragments was rhomboidal, pencil like or trapezoidal were included in this study. This was done to prevent undue resection and sculpting during the surgical procedure. The Ilizarov frame was constructed pre-operatively to save operating time.

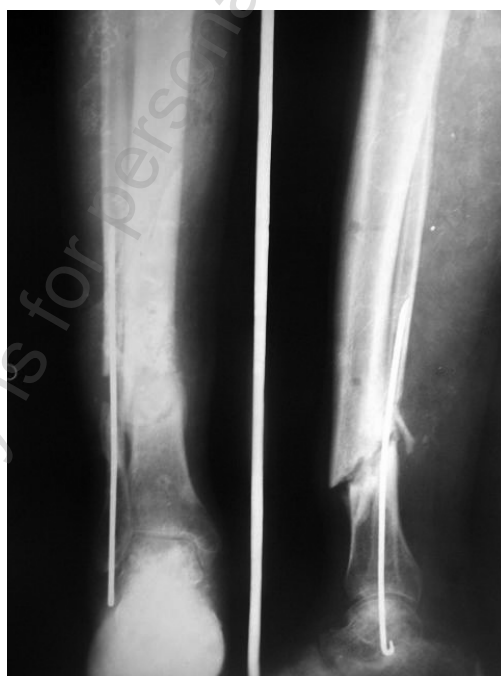

Fig. 1. Pre operative radiograph of the infected distal tibial non union

Intraoperatively the non union area was approached and sinuses, sequestrae and unhealthy soft tissue debrided aggressively. The ends of the two main bone fragments were exposed. The fragment which was preoperatively marked out as a peg was sculpted into an invaginating end [cortical peg]. The other end was converted into a receptacle for this peg [medullary hole]. The two ends were fitted into each other. In all cases a preliminary fibulectomy was done to allow acute shortening. Stability was tested by applying manual force in bending and shear. An invagination of at least 0.5 cm was achieved. It was ensured that the base of the peg be more than 1/3 of the diameter of the receiving end in both the antero-posterior and lateral planes. Wound closure in situations where docking exceeded 1 cm presented a problem of evagination, which was countered by approximating the wound edges only allowing it to epithelialise gradually (Fig. 2,3).

The preassembled Ilizarov frame was affixed and compression applied at the docking site. Only cases where the docking caused a shortening of less than 2.5 cm were included as no lengthening was done.

Postoperatively any angulation at the docking site as calculated from the radiographs was corrected by differential compression and distraction of the rings. Uniform compression was applied also to further stabilize the docking site. The radiographs after discharge were taken at 3 week intervals. As the procedure is such that the union is difficult to ascertain

radiographically in view of the overlap at the docking site inherent to the invagination, union was ascertained clinically by stress testing and radiologically by observing the melting of the clear margins of the peg. The stress testing was carried out by making the patient walk 50 meters after removing the threaded rods spanning the docking area. Lack of pain and mobility at the fracture site was interpreted as clinical union. The fixator was removed as an out-patient procedure and a patellar tendon bearing brace was applied for an additional 4 weeks.

The bone results were assessed according to the protocol laid down by the association for the study and application of the method of Ilizarov [4]. An excellent result was defined as union, no infection, deformity of less than 7° and leg length inequality of less than 2.5 cm; a good result was defined as union and any two of the other three criteria; a fair result was defined as union and one of the other criteria; and a poor result was defined as non-union or refracture, or as union in the absence of any of the other three criteria (Fig. 4).

The functional result was based on five criteria: a noteworthy limp, stiffness of adjacent joints (loss of more than 15° of motion), soft tissue sympathetic dystrophy (RSOD), pain that reduced activity or disturbed sleep and inactivity. The functional result was considered excellent if the patient was active and none of the other four criteria were applicable, good if the patient was active but one or two of the other

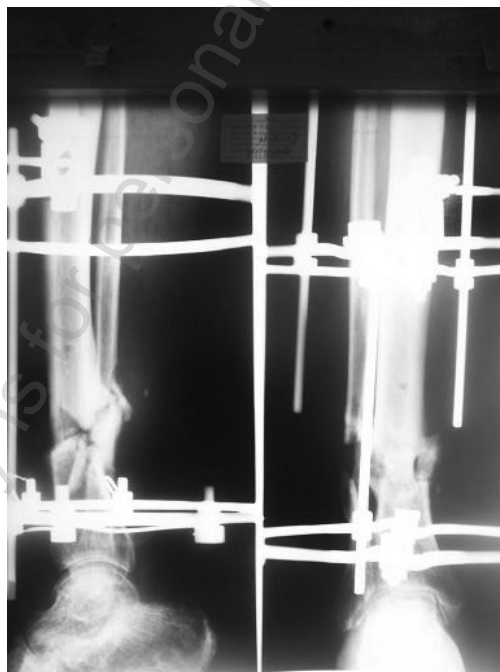

Fig. 2. Showing the radiograph of the docked site

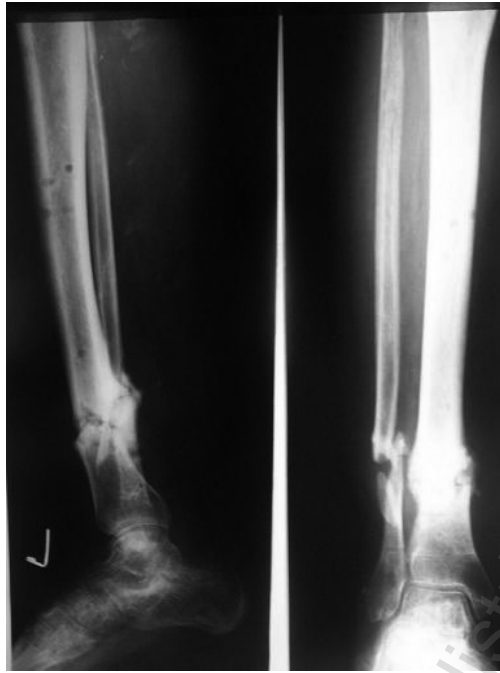

Fig. 3. Showing union at the docking site

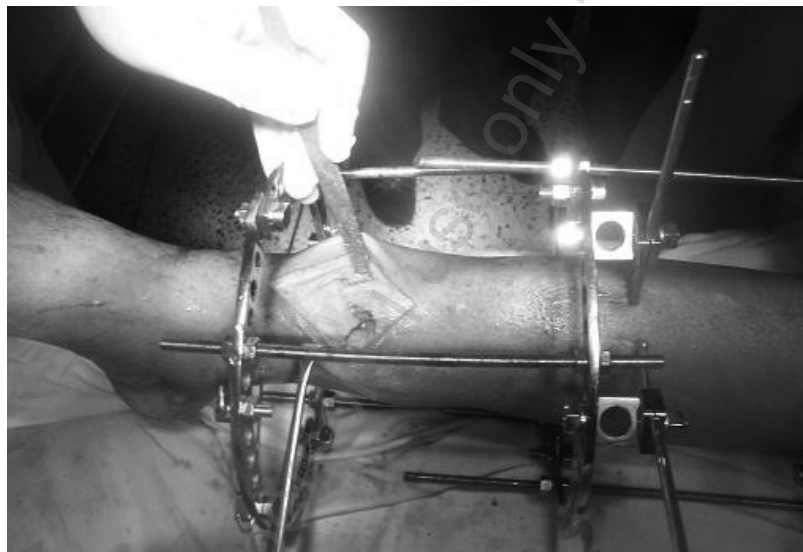

Fig. 4. Intra operative view of the invaginating docking

criteria were applicable, fair if the patient was active but three or four of the other criteria were applicable and poor if the patient was inactive [1].

## RESULTS

Acute peg in hole docking was done in all the cases. Drainage from the wound site persisted in almost all cases but dried out over a period of 2-12 weeks. The time to docking site union averaged 4 1/2 months. As the procedure is such that the union is difficult to ascertain radiographically in view of the overlap at the docking site inherent to the invagina-

tion, union was ascertained clinically by stress testing and radiologically by observing the melting of the clear margins of the peg. After removal of the fixator all patients were placed in a patellar tendon bearing brace for one month while ambulating. We encountered a total of 15 complications with 13 being problems, 1 obstacle and 1 true complication [7]. The true complication was formation of a ring sequestrum around an olive wire which continued to drain at the completion of treatment. In all the cases at final follow up the drainage at the docking site was absent. The soft tissues around the docking site showed good

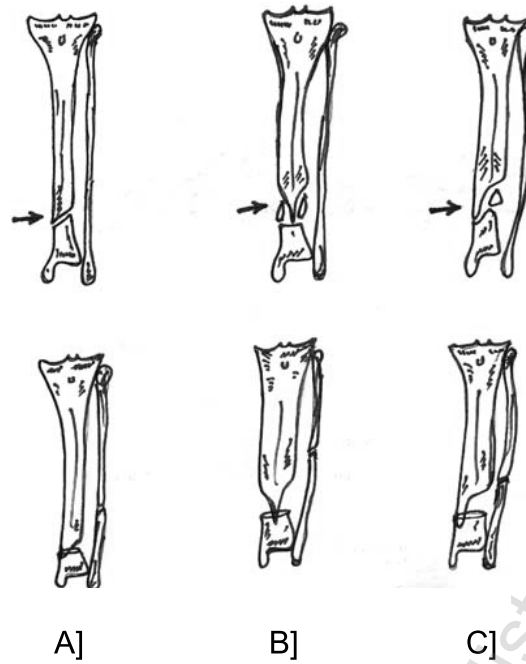


Fig 5. The three types of bone ends (arrows): a. Trapezoid. b. Pencil. c. Rhomboid. The peg in hole docking in the three theoretical situations is depicted by the line diagrams

Tab. 1. Showing the pre operative and post operative statistics of the patients

Sno	Age	Sex	Side	Cause	Number of previous surgeries	Pre op Duration [Months]	Problems	Obstacles	Complications	Union [Months]	Bone result and Functional result
1.	56	M	L	RTA	3	6	PTI			3	Excellent, excellent
2.	58	M	R	Fall	3	7	PTI			4	Good, Good
3.	63	F	R	RTA	3	5	PTI			5	Good, Good.
4.	61	M	L	RTA	4	12	edema			5	Good, excellent
5.	56	F	R	RTA	1	4	PTI			4	Good, Good.
6.	65	M	L	Fall	4	4	Metal allergy		Angulation at docking site.	6	Fair, Fair
7.	56	M	R	Fall	2	7	PTI			4	Excellent, excellent
8.	59	M	L	RTA	3	9	Pain			7	Good, excellent
9.	71	F	R	RTA	3	7	PTI, Dysthesia			3	Good, excellent
10.	68	M	L	RTA	2	7	PTI			3	Excellent, excellent
11.	66	M	R	Fall	5	5	PTI			4	Good, excellent
12.	59	F	R	RTA	6	13	PTI	Ring Sequestrum		5	Good, Good.

Sno: Serial Number  
M; Male  
F; Female.  
L; Left  
R; Right  
RTA; Road traffic accident  
PTI; Pin tract infection.

healing with absence of distal edema which might otherwise be expected in acute shortening. The average shortening at final follow up was 1.8 cms.

The bone results which were assessed according to the protocol laid down by the association for the study and application of the method of Ilizarov. Accordingly we had 3 excellent, 8 good and 1 fair result.

The functional result was calculated as per the Ilizarov criteria [1]. On this basis we had 7 excellent, 4 good and 1 fair result.

## DISCUSSION

The distal tibia is especially prone to non union in view of the poor soft tissue cover and consequent vascular compromise. Infected non union in this area is especially difficult due to its association with deformity, loss of bone, leg length discrepancy and soft tissue damage [7]. Bacteria, once they attach to bone, cover themselves with a biofilm that protects them from antimicrobials, opsonisation and phagocytosis. Antibiotic concentrations greater than 10-fold of the usual concentration are required, which cannot be safely achieved by systemic antibiotic therapy [8].

Conventionally, extensive debridement is used to get rid of the infected bone and soft tissue and to freshen the bone ends [9]. In this process, gaps are often created. Several methods have been used to fill these gaps. These include the use of cancellous bone grafts, vascularised free tissue transfer and electrical stimulation [3].

Bone grafting at the distal tibia is fraught with infective complications in view of the tenuous nature of the soft tissue, around this area. This often results in a high amount of graft loss [10]. Similarly, osteomyocutaneous free tissue transfer in an infected environment is fraught with risk and constraints of pedicle length [11].

The revolutionary techniques devised by Ilizarov have created a new potential for the salvage and reconstruction of the residuals of non union and chronic osteomyelitis. In the distal tibia the defects resulting from the debridement of the septic bone can be filled by one of the two methods.

1. Acute shortening.
2. Bone transport to fill the gap.

## REFERENCES

1. Ilizarov GA. Clinical application of the tension stress effect for limb lengthening. *Clin Orthop Relat Res* 1990; 250:8-26.
2. Aronson J, Johnson E, Harp JH. Local bone transportation for treatment of intercalary defects by the Ilizarov technique. Biomechanical and clinical considerations. *Clin Orthop* 1989; 243:71-79
3. Lenoble E, Lewertowski JM, Goutallier D. Reconstruction of compound tibial and soft tissue loss using a traction histogenesis technique. *J Trauma*;1995 39(2):356-360
4. Dhar SA, Mir MR, Ahmed MS, et al. Acute peg in hole docking in the management of infected non-union of long bones. *Int Orthop* 2007; 27: 17387- 474

In the distal tibia the use of external fixation requires immobilization of the ankle. Within the Ilizarov fixator the possible wire alignments do not allow enough stability in the sagittal plane. Transporting a fragment internally or externally often relies on bone grafting at the docking site or transformational osteogenesis. This requires additional time or extra surgical interventions.

Acute shortening with acceptance of up to 2.5 cm shortening was very well tolerated by this group of patients in a slightly older age group. Additional advantages of invaginating docking are enumerated below.

1. In the 12 bones that were acutely shortened and docked in an invaginating manner, bone grafting was not required in any case.
2. The time from surgery to union at the docking site averaged 4.5 months in our series. According to Dendrinis et al. the time taken for an intercalary segment to unite at the docking site after conventional internal transport is 24 weeks [7].
3. At the latest follow-up none of our cases had sustained a refracture at the docking site. Maini et al. reported a refracture rate of 10% in their series [12].
4. Adjustment of axial alignment post-operatively as the peg does not allow displacement at the docking site.
5. Reduction in the number of reoperations as the docking site does not need to be freshened. Only one case in our entire series required an additional surgical procedure for the débridement of a ring sequestrum.
6. Earlier institution of ankle physiotherapy as the invaginating peg assures stability.
7. The results of this series encourage application of this method more widely, as possible complications of oedema due to kinking of vessels and lymphatics which occurs in acute docking was hardly encountered.

## CONCLUSION

Acute peg-in-hole invaginating docking in infected non-union of the distal tibia addresses the basic principles of axial alignment, vascularity, stability and function simultaneously. It is a viable method of management in the older age group if shortening does not exceed 2.5 cms.

5. Schwartzman V, Choi SH, Schwartzman R. Tibial non-unions. Treatment tactics with the Ilizarov method. Orthop Clin North Am 1990; 21(4):639-653
6. Paley D. Problems, obstacles, and complications of limb lengthening by the Ilizarov technique. Clin Orthop Relat Res 1990; 250:81-104
7. Dendrinis GK, Kontos S, Lyritsis E. Use of the Ilizarov technique for treatment of non-union of the tibia associated with infection. J Bone Joint Surg 1995; 77-A:835-846
8. Nelson CL. The current status of material used for the depot delivery of drugs. CORR 2003; 427: 72-78.
9. Heppenstall RB. The present role of bone graft surgery in treating nonunion. Orthop Clin North Am 1984; 15(1):113-123
10. Papineau LJ, Alfageme A, Dalcourt JP et al . Osteomyelitis chronique; excision et griffe de spongieux a l'air libre apres mises a plat extensives. Int Orthop 1979; 3:165-176
11. Schwartz WM, Mears DC. The role of free-tissue transfers in lowerextremity reconstruction. Plast Reconstr Surg 1985; 76: 364-373

**Liczba słów/Word count:** 2393

**Tabele/Tables:** 1

**Ryciny/Figures:** 5

**Piśmiennictwo/References:** 11

*Adres do korespondencji / Address for correspondence*

*Shabir Ahmed Dhar, MD, PhD*

*Government Hospital for Bone and Joint Surgery, Bagat, Barzullah, Srinagar,  
Kashmir 190005, e-mail: shabirdhar@yahoo.co.in*

*Otrzymano / Received*

*11.01.2009 r.*

*Zaakceptowano / Accepted*

*15.06.2009 r.*

