Ortopedia Traumatologia Rehabilitacja
© MEDSPORTPRESS, 2009; 5(6); Vol. 11, 476-480

Rare Case of Bilateral Posterior Fracture Dislocation of the Shoulders Secondary to a Syncopal Episode

Khaled M Sarraf[1(A,B,C,D,E)], Amir Sadri[2(A,B,C,D,E)], Charles A Willis-Owen[2(A,B,C,D,E)]

[1] Department of Trauma and Orthopaedics, Chelsea and Westminster NHS Foundation Trust, London, UK
[2] Department of Trauma and Orthopaedics, The Hillingdon Hospital NHS Trust, London, UK

SUMMARY

Bilateral posterior fracture-dislocations of the shoulders are a rare injury that usually occurs secondary to a tonic-clonic seizure, electrocution or a high energy trauma. In this unique case, we present the first case of this injury resulting from a simple syncope in a 49 year old man with no history of epilepsy. He was fully investigated and no cause was found for his syncope. His shoulder fracture dislocations were reduced acutely and treated conservatively with full functional recovery.

Key words: bilateral, posterior fracture-dislocation, shoulder, syncope

BACKGROUND

Posterior shoulder dislocation is an uncommon injury and accounts for 1.7-4.3% of shoulder dislocations [1,2,3]. Bilateral posterior shoulder dislocations are even rarer injuries and are associated with reverse Hill-Sachs lesion, where a portion of the humeral head articular surface is fractured [2]. Most bilateral posterior fracture-dislocations of the shoulders reported are secondary to an epileptic seizure [3]; some cases were described secondary to high-energy direct trauma [4,5]. Posterior shoulder dislocations usually result from muscular imbalance between the comparatively stronger internal and weaker external rotators. Such injuries in the presence of trauma can be attributed to the axial load in the adducted, internal-rotated and flexed arm [3]. We report the first case of bilateral posterior shoulder fracture-dislocation secondary to a vasovagal episode.

CASE REPORT

A forty-nine-year-old healthy male teacher presented to the Emergency Department with bilateral painful shoulders after an episode of syncope. He felt unsteady and lightheaded prior to loss of consciousness and there was no witnessed tonic-clonic seizure. He regained consciousness promptly and complained of extreme pain in both shoulders. Of note, he also reported missing breakfast and the previous night's dinner before the event. There was no preceding shortness of breath, chest pain or palpitations, neither was there any associated neurological symptoms, intra-oral trauma or incontinence. He had no past history of seizures or syncope and was on no medications. He has not experienced any subsequent episodes.

On examination there was abnormal contour of both shoulders with evidence of mal-positioned glenohumeral joints. He was tender on palpation with limited shoulder movements and no neurovascular deficit. Antero-posterior and lateral scapular radiographs revealed bilateral posterior shoulder fracture-dislocations (Fig 1). These were reduced successfully in the emergency department under sedation with inline traction and external rotation. Both joints were stable after reduction and were immobilized in DonJoy® slings in the neutral position. Post reduction radiographs and further CT imaging demonstrated reverse Hill-Sachs lesions and bilateral lesser tuberosity fractures (Fig 2).

A thorough physical examination revealed no specific cause for syncope. He was investigated further with blood tests including electrolytes, he underwent echocardiography, twenty-four-hour electrocardiogram, electroencephalogram, and magnetic resonance imaging of his brain, all of which failed to show a cause for the collapse. A specialist neurolog-

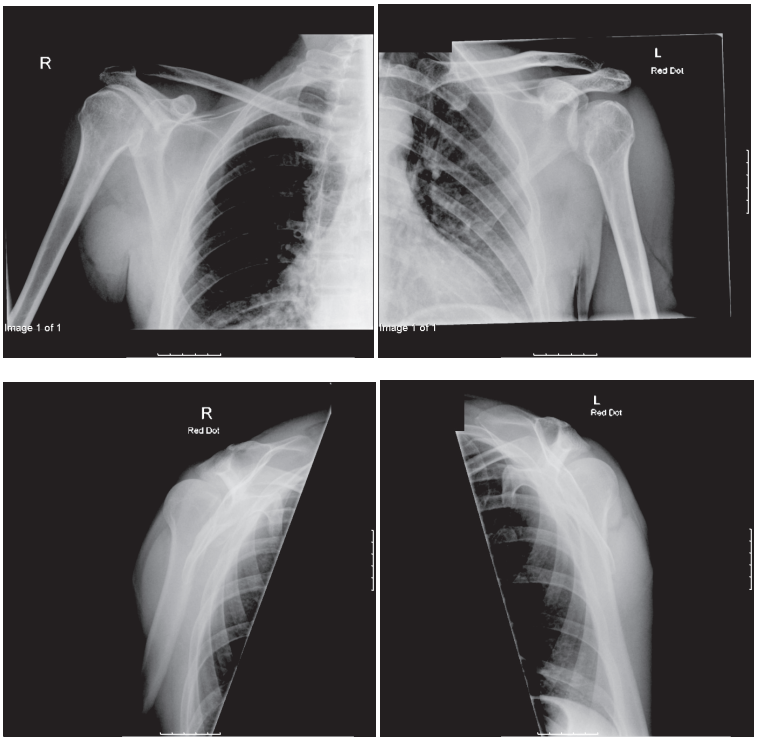

Fig. 1. Radiographs showing right and left posterior shoulder fracture-dislocation in the above patient (AP projection -top, Y projection -bottom)

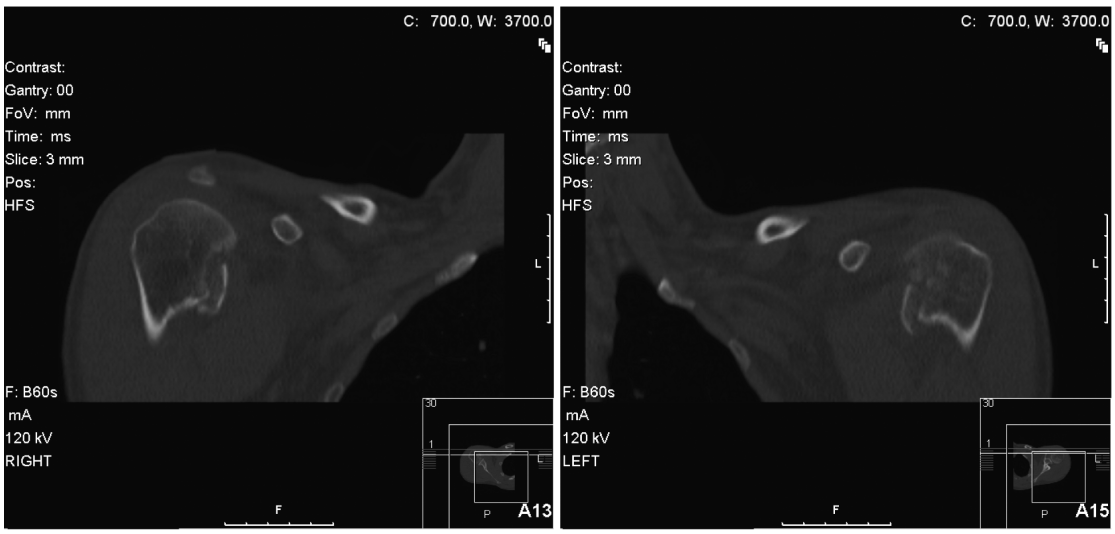

Fig. 2. Computer tomography showing post reduction lesser tuberosity fractures in both shoulders

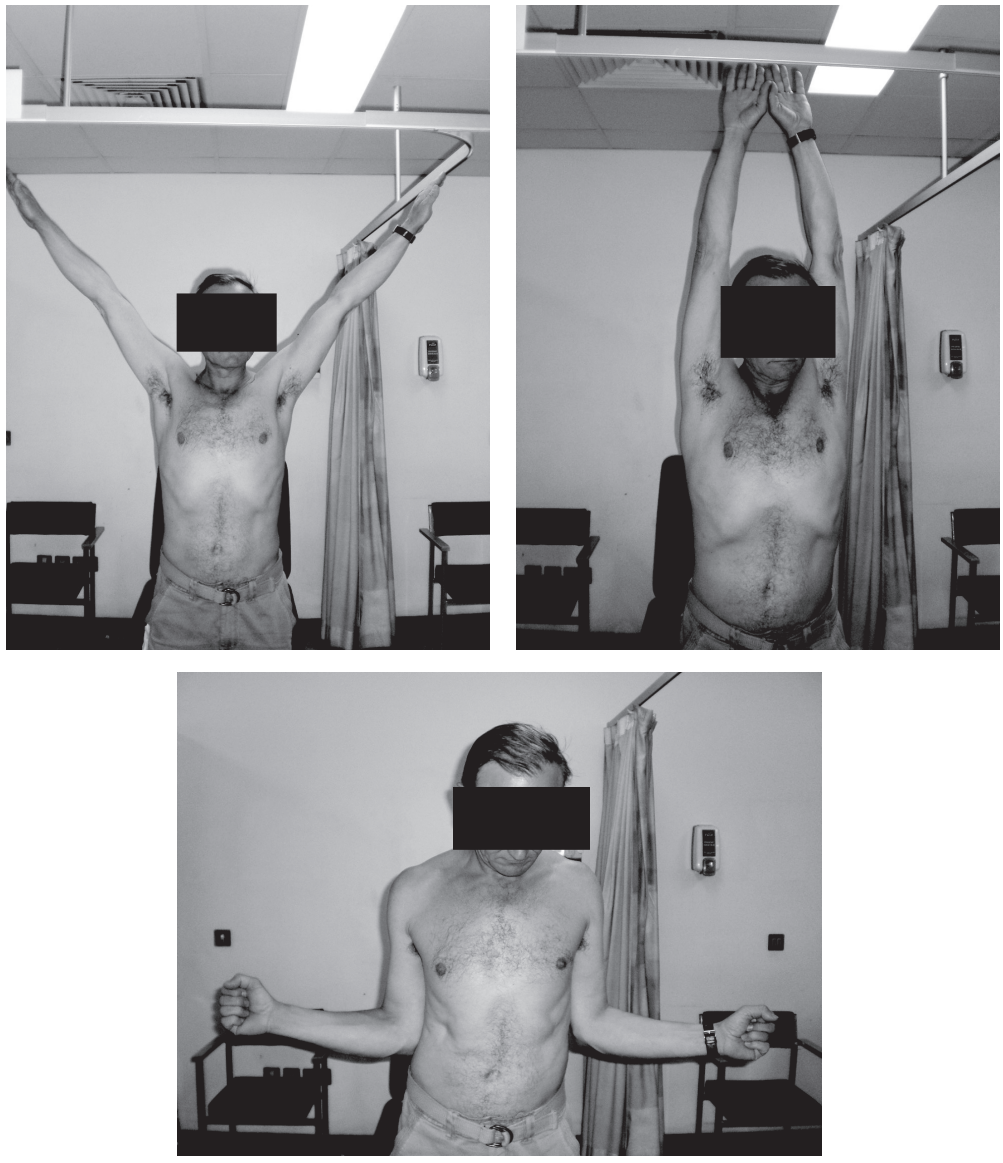

Fig. 3. Patient moving his shoulders in forward flexion, abduction and external rotation

ical opinion diagnosed collapse as a combination of mild hypoglycaemia and a vasovagal episode.

The patient made a full and complete recovery by 4 months, with full range of movement in both his shoulder joints. He had a negative posterior apprehension test. He has since been back to full time teaching and is independent in all activities of daily living with full muscle strength (Fig 3).

At eighteen months follow-up the patient was completely asymptomatic and was discharged.

DISCUSSION

This represents the first reported case of bilateral posterior glenohumeral dislocation subsequent to syncope. Whilst there was considerable suspicion of a seizural aetiology in this case, no part of the history, examination or investigations supported this.

Posterior dislocations of the shoulder account for 1.7%-4.3 of all shoulder dislocations with bilateral cases being even rarer (15% of posterior shoulder dislocations) [1,2,3,6]. They are due to the glenohumeral joint being axially loaded while in adduction, flexion and internal rotation. The internal rotator muscles are approximately twice as powerful as the external rotator muscles, thus a sudden contraction will cause the humeral head to dislocate. The patient is usually unable to abduct and externally rotate the shoulder [4]. Classically three types of posterior dislocation are described: subacromial, subglenoid and subspinous. A history of collapse and painful shoulder with or without obvious deformity should raise the suspicion of posterior dislocation, as it is described to be the most missed joint dislocation [6]. The prevalence of posterior dislocations is difficult to assess accurately because many cases remain undetected [7].

This case highlights the importance of taking a full history and a complete physical examination after an episode of un-explained collapse. This should include a simple screening examination of movements of all four limbs and the respective joints. Any symptoms of pain or stiffness in the glenohumeral joint should raise the suspicion of a potential dislocation whether it is anterior or posterior. In regard to posterior dislocation, the history usually includes seizure or electrocution, high energy trauma, and, as we saw in this case, an episode of syncope [8]. The patient usually describes significant pain and often complains of the shoulder 'not feeling right'. With frank posterior dislocations clinical examination would reveal a loss of the rounded contour of the deltoid muscle, and the arm would be held adducted and internally rotated and attempts at abduction and external rotation are painful. There is usually the inability to supinate or externally rotate the shoulder, and the corocoid process may be prominent. Chronic posterior dislocations of the shoulder may present in a similar clinical picture as a frozen shoulder. The posterior apprehension test can be used to aid the diagnosis; posterior translation stress is applied to the arm which is placed in flexion, adduction, and internal rotation. It is important to note that antero-posterior radiographs as well as lateral scapular views (or axial views) are of paramount importance in the acute setting to detect posterior dislocations of the glenoumeral joint.

Posterior dislocations can be associated with a defect in the posteromedial aspect of humeral head (reverse Hill-Sachs lesion), and there can also be associated fractures of the greater or lesser tuberosity and the posterior rim of the glenoid fossa. In cases of bilateral dislocation it can be difficult to image such pathologies with plain radiography due to pain and stiffness hindering adequate positioning of the patient. Computed Tomography (CT) can be useful in these situations in aiding diagnosis and assessing the extent of injury and fracture involvement.

Several factors determine how patients with bilateral posterior shoulder dislocation are managed. These include, age, previous level of activity, the defect size and time from injury to presentation1. Furthermore, the degree of their pre-morbid ligament laxity can play an integral role in rehabilitation and modality of treatment.

If the reverse Hill-Sachs lesion is less than one-fourth the articular surface of the humeral head, and the injury is less than three weeks old, closed reduction under general anaesthetic is most effective. Dislocations outside the above criteria have been shown to be nearly impossible to reduce using a closed method and require open reduction [3]. If the joint post reduction is deemed stable it is immobilized in neutral for 3 weeks. If unstable it can be immobilized with the arm by the side, with 20o of external rotation for 6 weeks.

CONCLUSION

This is the first case of bilateral posterior fracture-dislocation of the shoulder secondary to low grade trauma from a vasovagal attack. In order for such injuries not to be missed, the range of motion of the shoulders should always be assessed in patients who arrive in the Emergency Department with unexplained syncope, as well as seizures or traumatic injuries.

In our case reduction of the shoulder joint in the acute setting achieved excellent results despite the

concurrent fractures. The patient has resumed full activities of daily living with no limitations. The principle of management lies in a high degree of suspicion and adequate imaging (radiographs and CT) so that the diagnosis is not missed or delayed, and the extent of the injury is fully assessed. Treatment depends on several factors, but time from injury to diagnosis is of paramount importance.

REFERENCES

1. Iosifidis MI, Giannoulis I, Traios S, Giantsis G. Simultaneous bilateral posterior dislocation of the shoulder: diagnostic problems and management. A case report. Knee Surg Sports Traumatol Arthrosc 2006;14(8):766-70
2. Singh BJ, Sinha S, Brooks CA. Bilateral posterior fracture dislocation of shoulder: a case report. Euro J Ortho Surg & Trauma 2004;14(2):116-118
3. Rockwood C. The diagnosis of acute posterior dislocation of the shoulder. J Bone Joint Surg Am 1965;46:1220
4. Shaw JL. Bilateral posterior fracture-dislocation of the shoulder and other trauma caused by convulsive seizures. J Bone Joint Surg Am 1971;53(7):1437–1440
5. Hawkins RJ, Neer CS II et al. Locked posterior dislocation of the shoulder. J Bone Joint Surg Am 1987;69(1):9-18
6. Robinson CM, Aderinto J. Posterior shoulder dislocations and fracture dislocations. J Bone Joint Surg Am 2005;87(3): 639-650
7. Dorgan JA. Posterior dislocation of shoulder. Am J Surg 1955;89:890–900
8. Becker R, Weyand F. Rare, bilateral posterior shoulder dislocation. A case report. Unfallchirurg 1990;93(2):66–68

Liczba słów/Word count: 1565 **Tabele/Tables:** 0 **Ryciny/Figures:** 3 **Piśmiennictwo/References:** 8

K M Sarraf
Department of Orthopaedic Surgery Chelsea and Westminster NHS Foundation Trust
369 Fulham Road, London SW10 9NH, United Kingdom
Tel. +44 20 8746 8022, e-mail: ksarraf@gmail.com

Otrzymano / Received *11.06.2009 r.*
Zaakceptowano / Accepted *31.09.2009 r.*